National Comprehensive Cancer Network®

NCCN Clinical Practice Guidelines in Oncology (NCCN Guidelines®)

Appendiceal Neoplasms and Cancers

Version 2.2026 — April 10, 2026

NCCN recognizes the importance of clinical trials and encourages participation when applicable and available. Trials should be designed to maximize inclusiveness and broad representative enrollment.

Version 2.2026, 04/10/26 © 2026 National Comprehensive Cancer Network® (NCCN®), All rights reserved. NCCN Guidelines® and this illustration may not be reproduced in any form without the express written permission of NCCN.

PLEASE NOTE that use of this NCCN Content is governed by the End-User License Agreement, and you MAY NOT distribute this Content or use it with any artificial intelligence model or tool.
Printed by Máximo López Chenlo on 5/4/2026 6:12:29 PM. Copyright © 2026 National Comprehensive Cancer Network, Inc. All Rights Reserved.

NCCN Guidelines Version 2.2026
Appendiceal Neoplasms and Cancers

***Al B. Benson III, MD/Chair †**
Robert H. Lurie Comprehensive Cancer Center of Northwestern University

***Alan P. Venook, MD/Vice-Chair † ‡**
UCSF Helen Diller Family Comprehensive Cancer Center

***Stacey A. Cohen, MD/Lead †**
Fred Hutchinson Cancer Center

***Mohamed Adam, MD/Co-Lead ¶**
UCSF Helen Diller Family Comprehensive Cancer Center

***Manju Ambelil, MD ≠**
Fox Chase Cancer Center

Alexander Bray, MD, PhD †
O'Neal Comprehensive Cancer Center at UAB

George J. Chang, MD, MS, MHCM ¶
The University of Texas MD Anderson Cancer Center

Kristen K. Ciombor, MD †
Vanderbilt-Ingram Cancer Center

Madison Conces, MD ‡ †
Case Comprehensive Cancer Center/ University Hospitals Seidman Cancer Center and Cleveland Clinic Taussig Cancer Institute

Dustin Deming, MD †
University of Wisconsin Carbone Cancer Center

Vaia Florou, MD, MS ‡ Þ
Huntsman Cancer Institute at the University of Utah

Ignacio Garrido-Laguna, MD, PhD †
Huntsman Cancer Institute at the University of Utah

Jean L. Grem, MD †
Fred & Pamela Buffett Cancer Center

Carla Harmath, MD ф
The UChicago Medicine Comprehensive Cancer Center

Paul Haste, MD ф
Indiana University Melvin and Bren Simon Comprehensive Cancer Center

J. Randolph Hecht, MD †
UCLA Jonsson Comprehensive Cancer Center

J. Kevin Hicks, PharmD, PhD Σ
Moffitt Cancer Center

Sarah Hoffe, MD §
Moffitt Cancer Center

Steven Hunt, MD ¶
Siteman Cancer Center at Barnes-Jewish Hospital and Washington University School of Medicine

Hisham Hussan, MD ¤
UC Davis Comprehensive Cancer Center

Kimberly L. Johung, MD, PhD §
Yale Cancer Center/Smilow Cancer Hospital

***Nora Joseph, MD ≠**
University of Michigan Rogel Cancer Center

Natalie Kirilcuk, MD ¶
Stanford Cancer Institute

Midhun Malla, MD, MS †
O'Neal Comprehensive Cancer Center at UAB

***Rifat Mannan, MD ≠**
City of Hope National Medical Center

Jennifer K. Maratt, MD, MS ¤
Indiana University Melvin and Bren Simon Comprehensive Cancer Center

Wells A. Messersmith, MD †
University of Colorado Cancer Center

Jeffrey Meyer, MD, MS §
Johns Hopkins Kimmel Cancer Center

Jeffrey Meyerhardt, MD, MPH †
Dana-Farber Brigham and Women's Cancer Center

Eric D. Miller, MD, PhD §
The Ohio State University Comprehensive Cancer Center - James Cancer Hospital and Solove Research Institute

Mary F. Mulcahy, MD ‡ †
Robert H. Lurie Comprehensive Cancer Center of Northwestern University

Steven Nurkin, MD, MS, MBA ¶
Roswell Park Comprehensive Cancer Center

Hitendra Patel, MD †
UC San Diego Moores Cancer Center

Katrina Pedersen, MD, MS †
Mayo Clinic Comprehensive Cancer Center

Leonard Saltz, MD † ‡ Þ
Memorial Sloan Kettering Cancer Center

Charles Schneider, MD †
Abramson Cancer Center at the University of Pennsylvania

David Shibata, MD ¶
St. Jude Children's Research Hospital/The University of Tennessee Health Science Center

Benjamin Shogan, MD ¶
The UChicago Medicine Comprehensive Cancer Center

Laurie Singer ¥
DoubleLL Productions

Constantinos T. Sofocleous, MD, PhD ф
Memorial Sloan Kettering Cancer Center

Anna Tavakkoli, MD, MSc ¤
UT Southwestern Simmons Comprehensive Cancer Center

Christopher G. Willett, MD §
Duke Cancer Institute

Christina Wu, MD †
Mayo Clinic Comprehensive Cancer Center

NCCN
Faviolla Baez-Cruz, PhD
Lisa Gurski, PhD
Frankie Jones

ф Diagnostic/Interventional radiology
¤ Gastroenterology
‡ Hematology/Hematology oncology
Þ Internal medicine
† Medical oncology
≠ Pathology
¥ Patient advocacy
Σ Pharmacology/ Pharmacy
§ Radiotherapy/Radiation oncology
¶ Surgery/Surgical oncology
* Discussion Section Writing Committee

NCCN Guidelines Panel Disclosures

Version 2.2026, 04/10/26 © 2026 National Comprehensive Cancer Network® (NCCN®), All rights reserved. NCCN Guidelines® and this illustration may not be reproduced in any form without the express written permission of NCCN.

PLEASE NOTE that use of this NCCN Content is governed by the End-User License Agreement, and you MAY NOT distribute this Content or use it with any artificial intelligence model or tool.
Printed by Máximo López Chenlo on 5/4/2026 6:12:29 PM. Copyright © 2026 National Comprehensive Cancer Network, Inc. All Rights Reserved.

NCCN Guidelines Version 2.2026
Appendiceal Neoplasms and Cancers

NCCN Appendiceal Neoplasms and Cancers Panel Members

Clinical Presentations and Primary Treatment
- Workup for Suggested Appendiceal Neoplasm or Cancer/Confirmed Appendiceal Neoplasm or Cancer/Incidental Finding (APP-1)
- Pathology Review Results (APP-2)
- Management of Localized Disease for LAMN/HAMN and AA/GCA/UC-NOS (APP-3)
- Metastatic LAMN/HAMN: Peritoneal-Only Disease (APP-4)
- Workup for Recurrence (APP-5)
- Biopsy-Proven Recurrence (APP-5A)
- Surveillance: LAMN/HAMN and No High-Grade Peritoneal Deposit (APP-6)
- Metastatic AA/GCA/UC-NOS: Peritoneal-Only Appendix Cancer (APP-7)
- Surveillance: AA/GCA/UC-NOS (APP-8)
- Management of Extraperitoneal Disease (APP-9)

Principles of Imaging (APP-A)
Principles of Pathology and Molecular Review (APP-B)
Principles of Surgery and CRS/IPCT (APP-C)
Principles of Palliative Systemic Therapy (APP-D)
Principles of Survivorship (APP-E)

Staging (ST-1)
Abbreviations (ABBR-1)

Find an NCCN Member Institution: https://www.nccn.org/home/member-institutions.

NCCN Categories of Evidence and Consensus: All recommendations are category 2A unless otherwise indicated.

See NCCN Categories of Evidence and Consensus.

The NCCN Guidelines® are a statement of evidence and consensus of the authors regarding their views of currently accepted approaches to treatment. Any clinician seeking to apply or consult the NCCN Guidelines is expected to use independent medical judgment in the context of individual clinical circumstances to determine any patient's care or treatment. The National Comprehensive Cancer Network® (NCCN®) makes no representations or warranties of any kind regarding their content, use or application and disclaims any responsibility for their application or use in any way. The NCCN Guidelines are copyrighted by National Comprehensive Cancer Network®. All rights reserved. The NCCN Guidelines and the illustrations herein may not be reproduced in any form without the express written permission of NCCN. ©2026.

PLEASE NOTE that use of this NCCN Content is governed by the End-User License Agreement, and you MAY NOT distribute this Content or use it with any artificial intelligence model or tool.
Printed by Máximo López Chenlo on 5/4/2026 6:12:29 PM. Copyright © 2026 National Comprehensive Cancer Network, Inc. All Rights Reserved.

Updates in Version 2.2026 of the NCCN Guidelines for Appendiceal Neoplasms and Cancers:

APP-1
- Footnote a modified: ~~FDA added a Black Box warning to the capecitabine label, recommending to test patients for genetic variants of DPYD prior to initiating capecitabine unless immediate treatment is necessary.~~ For information on DPYD testing and fluoropyrimidine-associated toxicity, see the NCCN Guidelines for Colon Cancer.

MS-1
- The Discussion section, which reflects the recommendations in the algorithm, has been added.

Version 2.2026, 04/10/26 © 2026 National Comprehensive Cancer Network® (NCCN®), All rights reserved. NCCN Guidelines® and this illustration may not be reproduced in any form without the express written permission of NCCN.

PLEASE NOTE that use of this NCCN Content is governed by the End-User License Agreement, and you MAY NOT distribute this Content or use it with any artificial intelligence model or tool.
Printed by Máximo López Chenlo on 5/4/2026 6:12:29 PM. Copyright © 2026 National Comprehensive Cancer Network, Inc. All Rights Reserved.

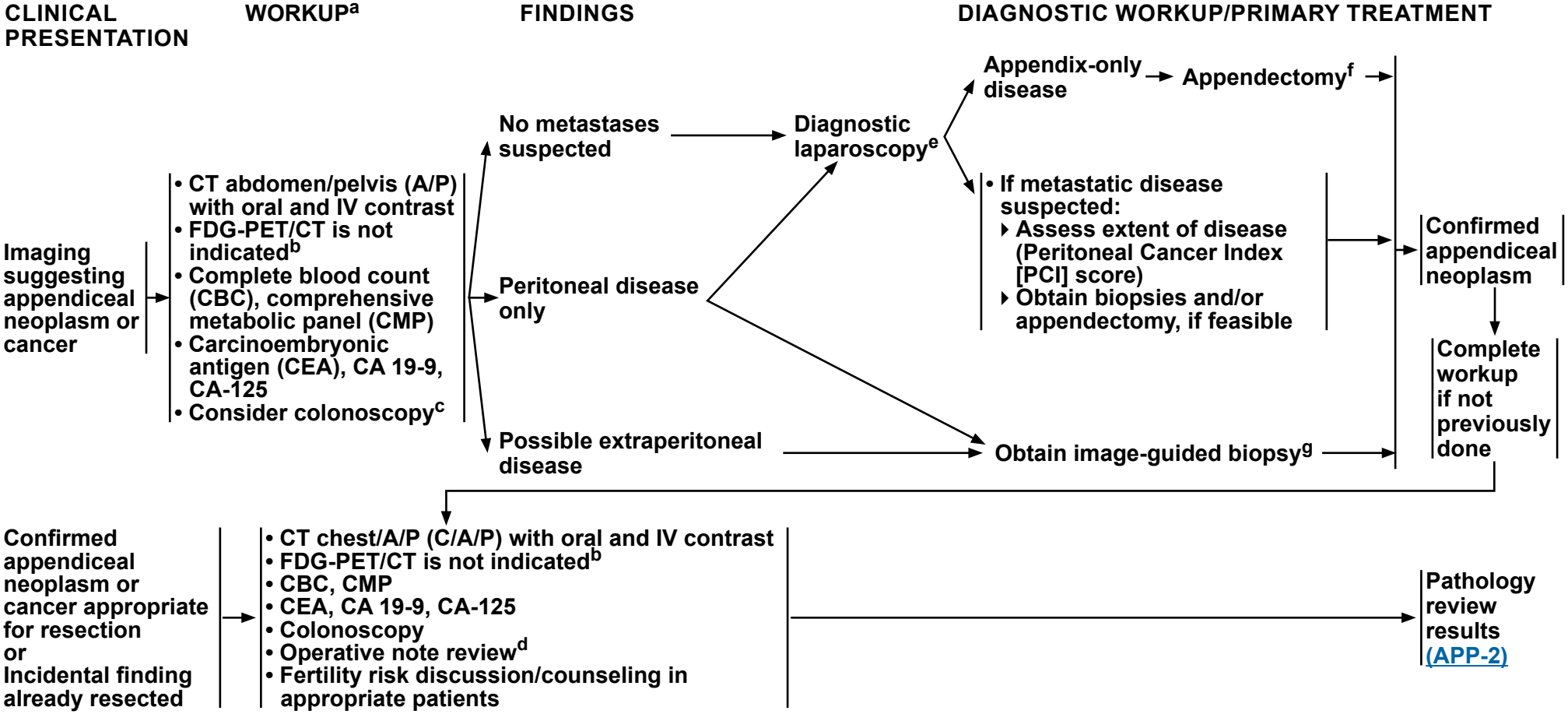

[a] For information on *DPYD* testing and fluoropyrimidine-associated toxicity, see the NCCN Guidelines for Colon Cancer.
[b] Use of FDG-PET/CT is only considered in rare circumstances where CT findings are indeterminate or when CT with contrast is not possible. See Principles of Imaging (APP-A).
[c] Colonoscopy is needed for a confirmed appendiceal neoplasm to rule out other primary lesions. This could be done concurrently with the other diagnostic studies, but should not delay treatment.
[d] Thorough review of operative notes is encouraged upon confirmation of appendiceal neoplasm in order to rule out more aggressive disease (eg, perforation, ascites present, signs of mucin).
[e] Diagnostic laparoscopy should be performed by a surgeon with experience in this disease process.
[f] See Principles of Surgery and CRS/IPCT (APP-C) for circumstances where a right hemicolectomy may be recommended.
[g] For peritoneal-only disease, image-guided biopsy is preferred for lesions that are safely accessible percutaneously when a non-surgical approach is preferred to confirm the diagnosis (eg, due to comorbidities or extraperitoneal disease). If inaccessible, surgical biopsy may be needed for diagnostic confirmation.

Note: All recommendations are category 2A unless otherwise indicated.

Version 2.2026, 04/10/26 © 2026 National Comprehensive Cancer Network® (NCCN®), All rights reserved. NCCN Guidelines® and this illustration may not be reproduced in any form without the express written permission of NCCN.

PLEASE NOTE that use of this NCCN Content is governed by the End-User License Agreement, and you MAY NOT distribute this Content or use it with any artificial intelligence model or tool.
Printed by Máximo López Chenlo on 5/4/2026 6:12:29 PM. Copyright © 2026 National Comprehensive Cancer Network, Inc. All Rights Reserved.

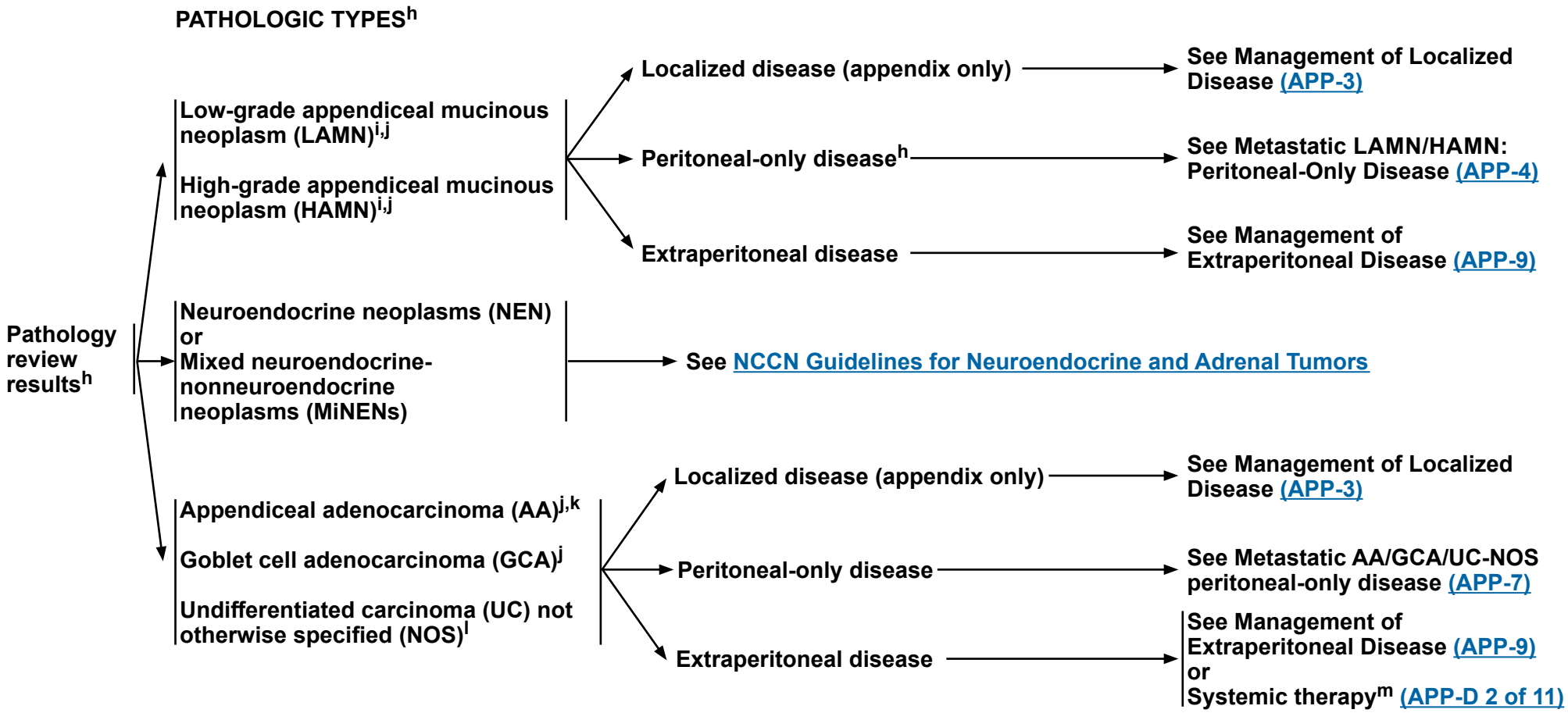

[h] Primary and metastatic disease are evaluated separately. See Principles of Pathology and Molecular Review (APP-B).

[i] Lesions with extra-appendiceal acellular mucin are considered low risk for dissemination. Lesions with extra-appendiceal mucin-containing neoplastic epithelium are considered high risk for recurrence or peritoneal dissemination and the peritoneal-only disease pathway would be followed.

[j] Lesions containing ≤50% signet-ring cells are classified as mucinous adenocarcinomas with signet-ring cells. Tumors containing >50% signet-ring cells are classified as signet-ring cell carcinomas. Signet-ring cell carcinomas are associated with a high level of metastasis and worse prognosis.

[k] Lesions containing ≤50% of mucin are classified as non-mucinous adenocarcinomas. Tumors containing >50% mucin are considered mucinous adenocarcinomas.

[l] UCs only show epithelial marker expression if there is no histologic, immunohistochemical, or molecular indicators of the tissue of origin. Nagtegaal ID, et al. Histopathology 2020;76:182-188.

[m] Biomarker testing is recommended, although there may be a higher rate of assay failure if specimen has low cellularity. See Principles of Pathology and Molecular Review (APP-B).

Note: All recommendations are category 2A unless otherwise indicated.

Version 2.2026, 04/10/26 © 2026 National Comprehensive Cancer Network® (NCCN®), All rights reserved. NCCN Guidelines® and this illustration may not be reproduced in any form without the express written permission of NCCN.

PLEASE NOTE that use of this NCCN Content is governed by the End-User License Agreement, and you MAY NOT distribute this Content or use it with any artificial intelligence model or tool.
Printed by Máximo López Chenlo on 5/4/2026 6:12:29 PM. Copyright © 2026 National Comprehensive Cancer Network, Inc. All Rights Reserved.

MANAGEMENT OF LOCALIZED DISEASE[n]

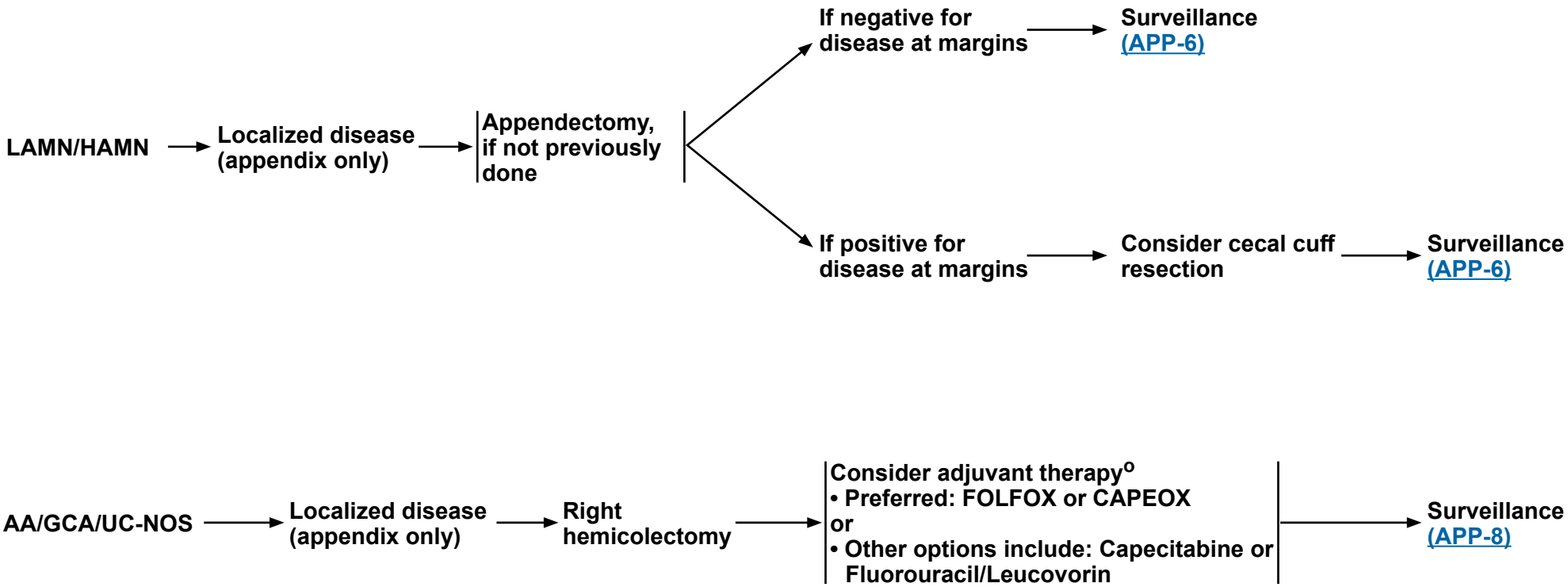

[n] Multidisciplinary team evaluation, including formal surgical evaluation.
[o] Strongly consider adjuvant chemotherapy for patients with nodal disease or perforation noted at the time of surgery. May be considered in other instances depending on high-risk features (extrapolating from colon cancer, these features may be: poorly differentiated/undifferentiated histology; lymphatic/vascular invasion; bowel obstruction; <12 lymph nodes examined; perineural invasion [PNI]; localized perforation; close, indeterminate, positive margins; or high-tier tumor budding). Circulating tumor (ctDNA) is prognostic, but not predictive.

Note: All recommendations are category 2A unless otherwise indicated.

Version 2.2026, 04/10/26 © 2026 National Comprehensive Cancer Network® (NCCN®), All rights reserved. NCCN Guidelines® and this illustration may not be reproduced in any form without the express written permission of NCCN.

PLEASE NOTE that use of this NCCN Content is governed by the End-User License Agreement, and you MAY NOT distribute this Content or use it with any artificial intelligence model or tool.
Printed by Máximo López Chenlo on 5/4/2026 6:12:29 PM. Copyright © 2026 National Comprehensive Cancer Network, Inc. All Rights Reserved.

METASTATIC LAMN/HAMN: PERITONEAL-ONLY DISEASE[n]

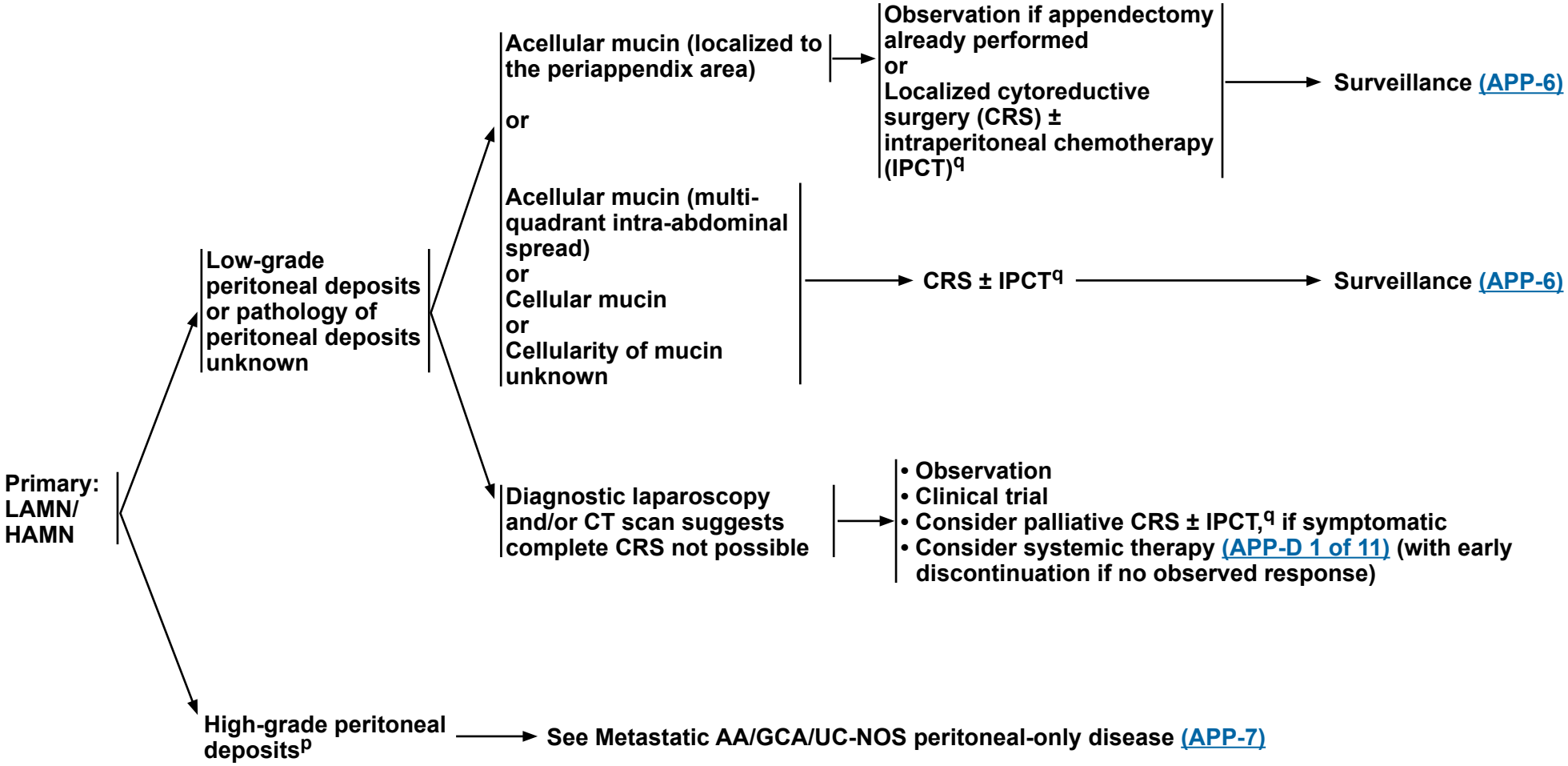

[n] Multidisciplinary team evaluation, including formal surgical evaluation.
[p] High-grade peritoneal deposits behave clinically like high-risk disease and should follow those treatment pathways, even if the primary is low grade.
[q] Principles of Surgery and CRS/IPCT (APP-C).

Note: All recommendations are category 2A unless otherwise indicated.

Version 2.2026, 04/10/26 © 2026 National Comprehensive Cancer Network® (NCCN®), All rights reserved. NCCN Guidelines® and this illustration may not be reproduced in any form without the express written permission of NCCN.

PLEASE NOTE that use of this NCCN Content is governed by the End-User License Agreement, and you MAY NOT distribute this Content or use it with any artificial intelligence model or tool.
Printed by Máximo López Chenlo on 5/4/2026 6:12:29 PM. Copyright © 2026 National Comprehensive Cancer Network, Inc. All Rights Reserved.

WORKUP FOR RECURRENCE[n]

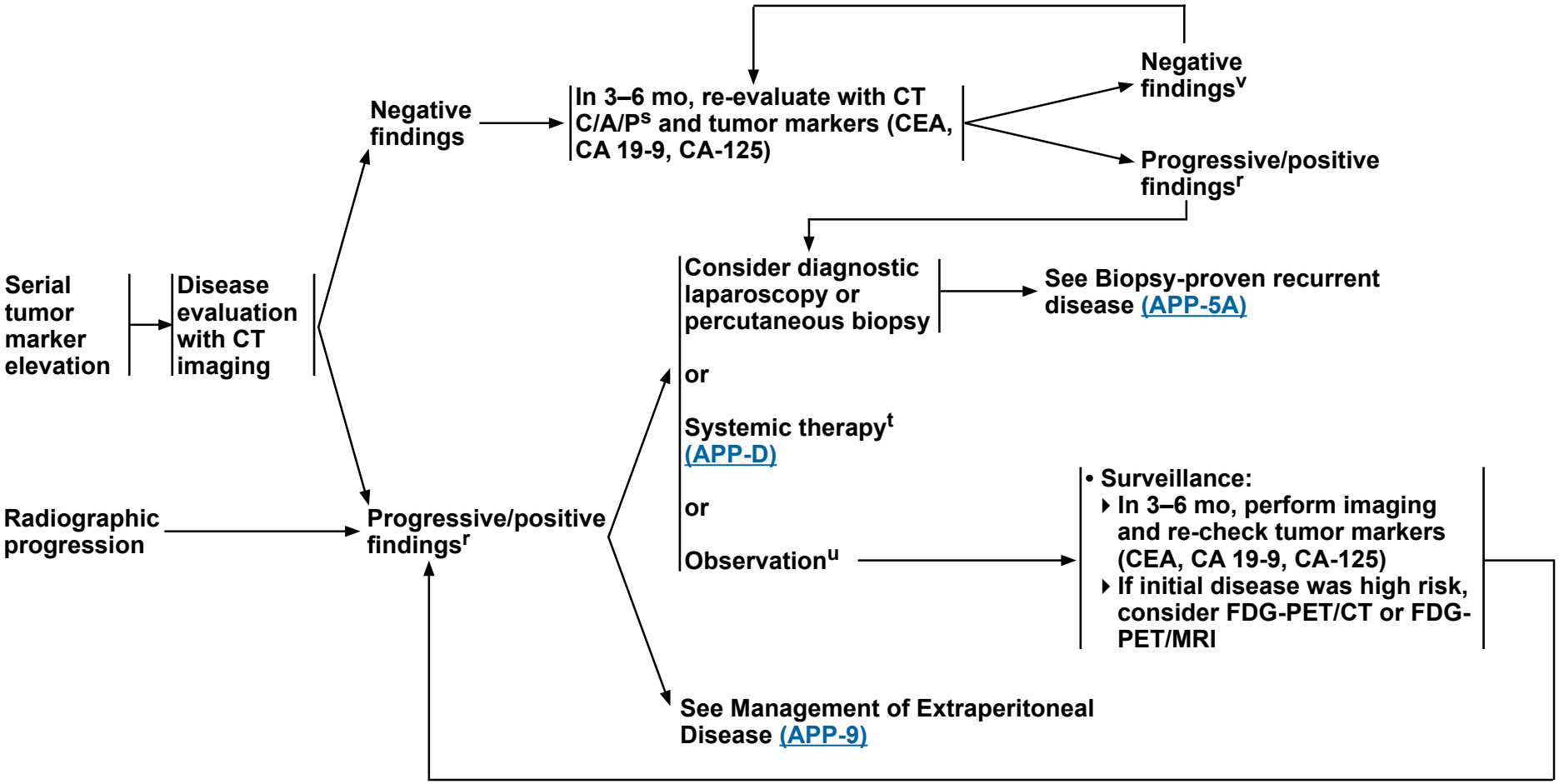

[n] Multidisciplinary team evaluation, including formal surgical evaluation.
[r] ctDNA assays are not recommended in this setting. These assays have a lower sensitivity for peritoneal disease and false negatives are common.
[s] If CT is normal and disease is considered high risk at initial diagnosis, consider FDG-PET/CT or FDG-PET/MRI.
[t] For progressive disease in a patient who is not a surgical candidate, systemic therapy may be considered without a biopsy. Follow the systemic therapy pathway according to the risk level of histology.
[u] In select cases per clinical judgment. For low-risk disease and indolent changes, observation with continued disease assessment may be considered.
[v] If consistently negative findings on multiple rounds of re-evaluation, interval may be lengthened to every 6–12 months.

Note: All recommendations are category 2A unless otherwise indicated.

Version 2.2026, 04/10/26 © 2026 National Comprehensive Cancer Network® (NCCN®), All rights reserved. NCCN Guidelines® and this illustration may not be reproduced in any form without the express written permission of NCCN.

PLEASE NOTE that use of this NCCN Content is governed by the End-User License Agreement, and you MAY NOT distribute this Content or use it with any artificial intelligence model or tool.
Printed by Máximo López Chenlo on 5/4/2026 6:12:29 PM. Copyright © 2026 National Comprehensive Cancer Network, Inc. All Rights Reserved.

BIOPSY-PROVEN RECURRENCE[n]

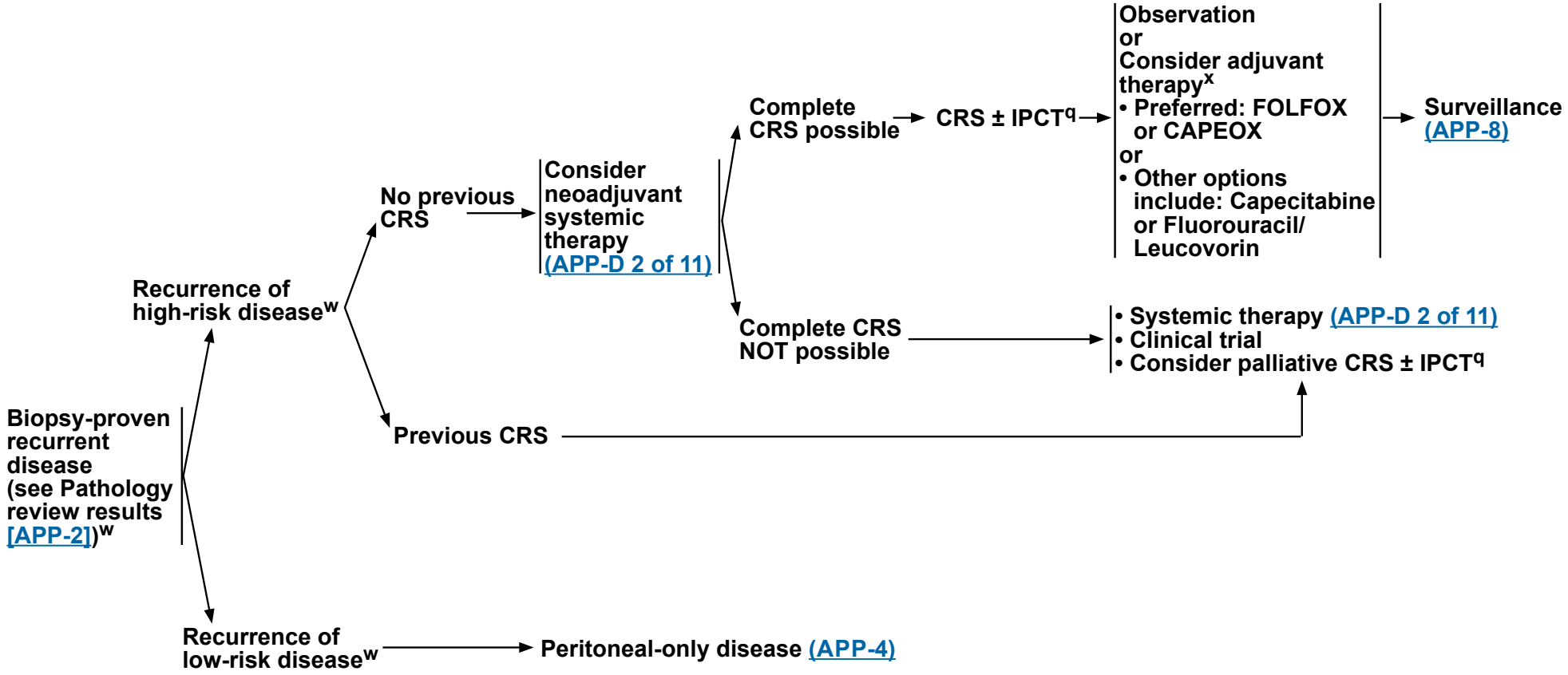

[n] Multidisciplinary team evaluation, including formal surgical evaluation.
[q] Principles of Surgery and CRS/IPCT (APP-C).
[w] Risk status should be according to pathology of metastatic disease; subsequent treatment should be based on the highest risk pathology found (thus, a low-risk primary with high-risk metastatic disease should be treated as per high-risk pathways).
[x] This recommendation has been extrapolated from colon cancer; duration of perioperative therapy should be limited to no more than 6 months.

Note: All recommendations are category 2A unless otherwise indicated.

Version 2.2026, 04/10/26 © 2026 National Comprehensive Cancer Network® (NCCN®), All rights reserved. NCCN Guidelines® and this illustration may not be reproduced in any form without the express written permission of NCCN.

PLEASE NOTE that use of this NCCN Content is governed by the End-User License Agreement, and you MAY NOT distribute this Content or use it with any artificial intelligence model or tool.
Printed by Máximo López Chenlo on 5/4/2026 6:12:29 PM. Copyright © 2026 National Comprehensive Cancer Network, Inc. All Rights Reserved.

SURVEILLANCE: LAMN/HAMN AND NO HIGH-GRADE PERITONEAL DEPOSIT

Resected localized disease[y] →

- History and physical examination every 6–12 mo for 2 y, then annually for up to 10 y
- CEA, CA 19-9, CA-125 every 6–12 mo for 2 y, then annually for up to 10 y[z]
- A/P CT or MRI every 6–12 mo from date of surgery for 2 years then every 12–24 mo for up to 10 y
- FDG-PET/CT is not indicated
- Colonoscopy, if no preoperative colonoscopy was done
- Principles of Survivorship (APP-E)

Resected metastatic disease →

- History and physical examination every 6 mo for 2 y, then annually for up to 10 y
- CEA, CA 19-9, CA-125 every 6–12 mo for 2 y, then annually for up to 10 y[z]
- C/A/P CT or MRI every 6 mo from date of surgery for 2 years then every 12 mo for up to 10 y
- FDG-PET/CT is not indicated
- Colonoscopy, if no preoperative colonoscopy was done
- Principles of Survivorship (APP-E)

→ **Rising tumor markers, unexplained abdominal symptoms, documented recurrence, or radiographic progression** → **See Recurrence (APP-5)**

[y] For completely resected LAMN confined to the appendix without high-risk features (eg, extra-appendiceal cellular mucin, presence of signet ring cells), surveillance may not be needed.
[z] It may not be necessary to measure all tumor markers at all surveillance timepoints as guided by prior marker elevations for the specific patient.

Note: All recommendations are category 2A unless otherwise indicated.

Version 2.2026, 04/10/26 © 2026 National Comprehensive Cancer Network® (NCCN®), All rights reserved. NCCN Guidelines® and this illustration may not be reproduced in any form without the express written permission of NCCN.

PLEASE NOTE that use of this NCCN Content is governed by the End-User License Agreement, and you MAY NOT distribute this Content or use it with any artificial intelligence model or tool.
Printed by Máximo López Chenlo on 5/4/2026 6:12:29 PM. Copyright © 2026 National Comprehensive Cancer Network, Inc. All Rights Reserved.

METASTATIC AA/GCA/UC-NOS PERITONEAL-ONLY APPENDIX CANCER[n]

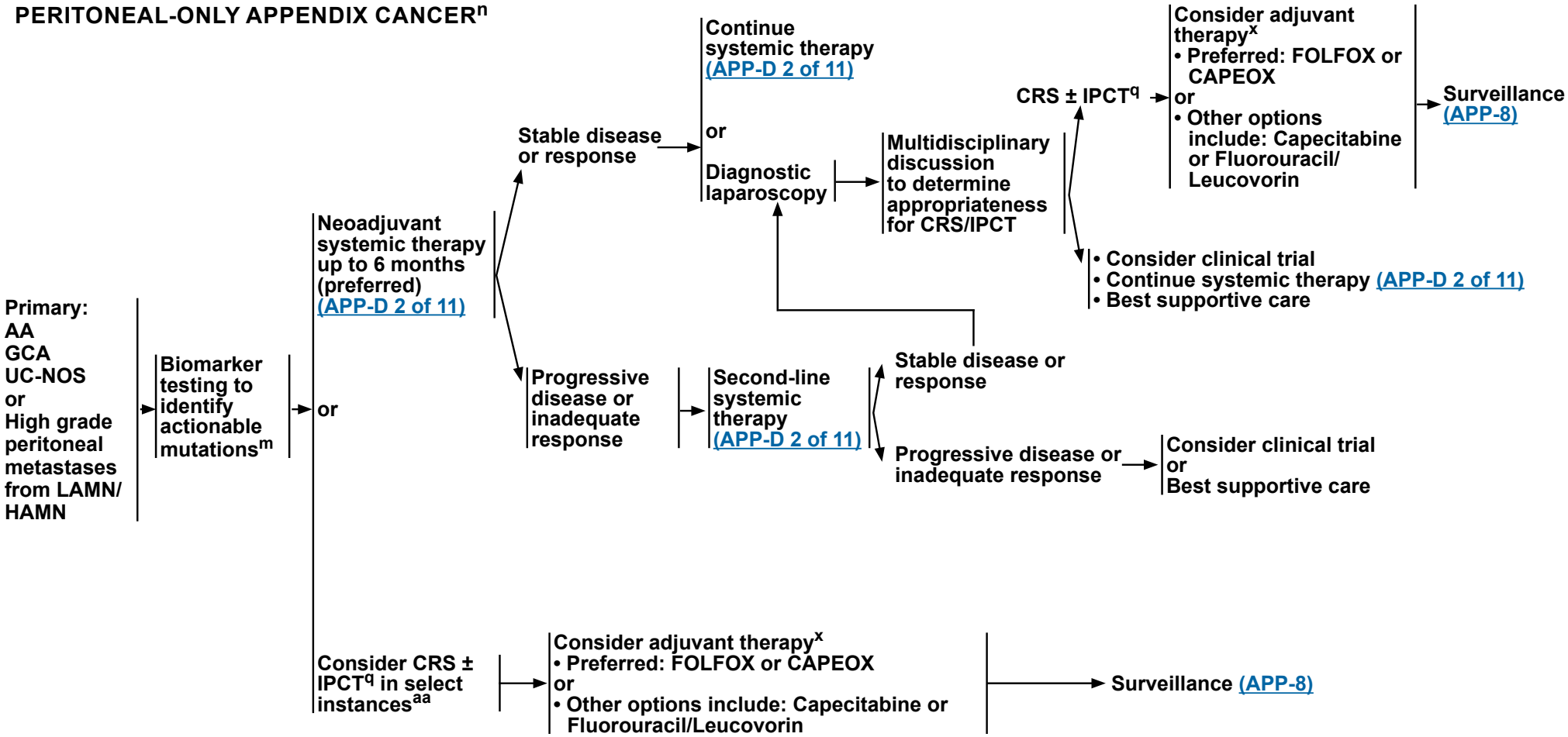

[m] Biomarker testing is recommended, although there may be a higher rate of assay failure if specimen has low cellularity. See Principles of Pathology and Molecular Review (APP-B).
[n] Multidisciplinary team evaluation, including formal surgical evaluation.
[q] Principles of Surgery and CRS/IPCT (APP-C).
[x] This recommendation has been extrapolated from colon cancer; duration of perioperative therapy should be limited to no more than 6 months.
[aa] Select instances including low disease burden and/or well-differentiated adenocarcinoma.

Note: All recommendations are category 2A unless otherwise indicated.

Version 2.2026, 04/10/26 © 2026 National Comprehensive Cancer Network® (NCCN®), All rights reserved. NCCN Guidelines® and this illustration may not be reproduced in any form without the express written permission of NCCN.

PLEASE NOTE that use of this NCCN Content is governed by the End-User License Agreement, and you MAY NOT distribute this Content or use it with any artificial intelligence model or tool.
Printed by Máximo López Chenlo on 5/4/2026 6:12:29 PM. Copyright © 2026 National Comprehensive Cancer Network, Inc. All Rights Reserved.

SURVEILLANCE: AA/GCA/UC-NOS

Resected localized disease →

- History and physical examination every 3–6 mo for 2 y, then every 6 mo for a total of 5 y
- CEA, CA 19-9, CA-125 every 3–6 mo for 2 y, then 6–12 mo for a total of 5 y
- C/A/P CT every 6–12 mo from date of surgery for a total of 5 y
- FDG-PET/CT is not indicated
- Colonoscopy, if no preoperative colonoscopy was done
- Principles of Survivorship (APP-E)

Resected metastatic disease, including resected LAMN/HAMN primary with high-grade metastatic disease →

- History and physical examination every 3–6 mo for 2 y, then every 6 mo for a total of 5 y
- CEA, CA 19-9, CA-125 every 3–6 mo for 2 y, then every 6 mo for a total of 5 y
- C/A/P CT every 3–6 mo for 2 years then every 6–12 mo for a total of 5 y
- FDG-PET/CT is not indicated
- Colonoscopy, if no preoperative colonoscopy was done
- Principles of Survivorship (APP-E)

→ **Rising tumor markers, unexplained abdominal symptoms, or documented recurrence** → **See Recurrence (APP-5)**

Note: All recommendations are category 2A unless otherwise indicated.

Version 2.2026, 04/10/26 © 2026 National Comprehensive Cancer Network® (NCCN®), All rights reserved. NCCN Guidelines® and this illustration may not be reproduced in any form without the express written permission of NCCN.

PLEASE NOTE that use of this NCCN Content is governed by the End-User License Agreement, and you MAY NOT distribute this Content or use it with any artificial intelligence model or tool.
Printed by Máximo López Chenlo on 5/4/2026 6:12:29 PM. Copyright © 2026 National Comprehensive Cancer Network, Inc. All Rights Reserved.

MANAGEMENT OF EXTRAPERITONEAL DISEASE[n]

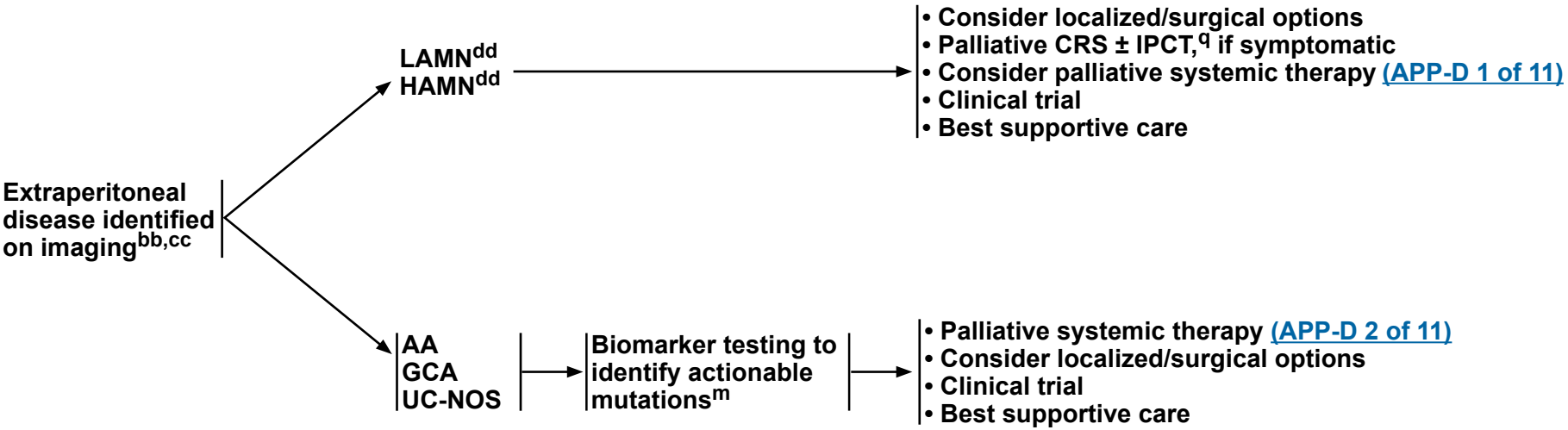

[m] Biomarker testing is recommended, although there may be a higher rate of assay failure if specimen has low cellularity. See Principles of Pathology and Molecular Review (APP-B).
[n] Multidisciplinary team evaluation, including formal surgical evaluation.
[q] Principles of Surgery and CRS/IPCT (APP-C).
[bb] If CT is not feasible, consider MRI of abdomen to differentiate between liver and extrahepatic disease.
[cc] Specify whether the metastases is within the liver parenchyma (extraperitoneal metastasis) or scalloping along the liver edge (still intraperitoneal metastasis).
[dd] It would be extremely unusual for low-risk disease to have extraperitoneal spread; therefore, pathologic confirmation is recommended to rule out high-risk disease.

Note: All recommendations are category 2A unless otherwise indicated.

Version 2.2026, 04/10/26 © 2026 National Comprehensive Cancer Network® (NCCN®), All rights reserved. NCCN Guidelines® and this illustration may not be reproduced in any form without the express written permission of NCCN.

PLEASE NOTE that use of this NCCN Content is governed by the End-User License Agreement, and you MAY NOT distribute this Content or use it with any artificial intelligence model or tool.
Printed by Máximo López Chenlo on 5/4/2026 6:12:29 PM. Copyright © 2026 National Comprehensive Cancer Network, Inc. All Rights Reserved.

PRINCIPLES OF IMAGING[1-5]

General

- It is important to note that imaging may be negative in the setting of peritoneal metastases, or that it may underestimate the peritoneal disease volume. Direct visualization (laparoscopic evaluation when feasible) should be performed for confirmation in the staging setting and when recurrence is suspected clinically and imaging findings are negative.
- The mainstay of staging imaging should consist of a CT of the C/A/P OR non-contrast CT of the chest with MRI of the A/P.
  - Evaluate local extent of tumor, presence of associated inflammation and/or perforation, and infiltration of adjacent structures and regional metastases.
  - Evaluate for distant metastases (ie, lymph nodes, lung, liver, peritoneum, other organs)
  - CT exam should be performed with oral and IV iodinated contrast, unless contraindicated.
  - If IV iodinated contrast is contraindicated due to severe allergy, then CT of the chest without contrast and MRI of the A/P with IV gadolinium-based contrast agent (GBCA) can be obtained instead.
  - In patients with chronic renal failure (estimated glomerular filtration rate [eGFR] <30 mL/min) who are not on dialysis, IV contrast material is also contraindicated, and IV GBCA such as gadofosveset trisodium, gadoxetate disodium, gadobenate dimeglumine, or gadoteridol may be used.
  - If both IV iodinated contrast and IV GBCA are contraindicated, CT of the chest without contrast and MRI of the A/P without contrast should be considered. PET/CT may also be considered as an alternate.
  - Consider MRI of the liver in cases where better resolution of indeterminate liver lesions is needed and/or MRI of select cases of hepatic metastases when planning metastasectomy or liver-directed therapies. In these cases, utilization of hepatocyte-specific GBCA is preferred for precise localization and quantification of metastases.

FDG-PET/CT

- FDG-PET/CT is usually not indicated. In select cases (ie, neuroendocrine neoplasm), DOTATATE PET/CT should be considered.
  - FDG-PET does not supplant a contrast-enhanced diagnostic CT or MRI and can be used to evaluate an equivocal finding on a contrast-enhanced CT or MRI, but should not be the preferred imaging study.
- FDG-PET may under-appreciate disease burden, especially for mucinous tumors.

Monitoring

- For treatment response monitoring, typically a CT of the A/P (in cases of resected localized disease), or CT of the C/A/P (in cases of resected metastatic disease) with oral and IV contrast, or non-contrast CT of the chest with MRI of the A/P should be used.
  - For patients who have had liver-directed therapy (ablation-based, ie, radiofrequency ablation [RFA], microwave ablation [MWA]; radiation-based, ie, radioembolization, stereotactic body radiation therapy [SBRT]), MRI of the liver is preferred over CT for the assessment of treatment response.
  - In select cases FDG-PET may be indicated to assess residual tumor viability if curative liver resection is contemplated, but should be done in partnership with a contrasted CT or MRI.
  - For mucinous tumors, MRI of the A/P may be preferred over CT as mucinous implants may be easier to distinguish from adjacent structures due to their T2 signal.

References

Note: All recommendations are category 2A unless otherwise indicated.

Version 2.2026, 04/10/26 © 2026 National Comprehensive Cancer Network® (NCCN®), All rights reserved. NCCN Guidelines® and this illustration may not be reproduced in any form without the express written permission of NCCN.

PLEASE NOTE that use of this NCCN Content is governed by the End-User License Agreement, and you MAY NOT distribute this Content or use it with any artificial intelligence model or tool.
Printed by Máximo López Chenlo on 5/4/2026 6:12:29 PM. Copyright © 2026 National Comprehensive Cancer Network, Inc. All Rights Reserved.

PRINCIPLES OF IMAGING
REFERENCES

[1] Chicago Consensus Working Group. The Chicago Consensus on peritoneal surface malignancies: Standards. Cancer 2020;126:2516-2524.
[2] Chicago Consensus Working Group. The Chicago Consensus on peritoneal surface malignancies: Management of appendiceal neoplasms. Cancer 2020;126:2525-2533.
[3] Expert Panel on Gastrointestinal Imaging; Korngold EK, Moreno C, Kim DH, et al. ACR Appropriateness Criteria® Staging of Colorectal Cancer: 2021 Update. J Am Coll Radiol 2022;19:S208-S222.
[4] Govaerts K, Chandrakumaran K, Carr NJ, et al. Single centre guidelines for radiological follow-up based on 775 patients treated by cytoreductive surgery and HIPEC for appendiceal pseudomyxoma peritonei. Eur J Surg Oncol 2018;44:1371-1377.
[5] Leonards LM, Pahwa A, Patel MK, et al. Neoplasms of the appendix: Pictorial review with clinical and pathologic correlation. Radiographics 2017;37:1059-1083.

Note: All recommendations are category 2A unless otherwise indicated.

Version 2.2026, 04/10/26 © 2026 National Comprehensive Cancer Network® (NCCN®), All rights reserved. NCCN Guidelines® and this illustration may not be reproduced in any form without the express written permission of NCCN.

PLEASE NOTE that use of this NCCN Content is governed by the End-User License Agreement, and you MAY NOT distribute this Content or use it with any artificial intelligence model or tool.
Printed by Máximo López Chenlo on 5/4/2026 6:12:29 PM. Copyright © 2026 National Comprehensive Cancer Network, Inc. All Rights Reserved.

PRINCIPLES OF PATHOLOGY AND MOLECULAR REVIEW

Appendiceal Cancer Appropriate for Resection

- Primary appendiceal neoplasms are rare and most often found incidentally during an appendectomy following clinical presentation of acute appendicitis.
- Individual management and treatment of primary appendiceal cancers are dependent on classification, grading, and staging.
- According to the most recent WHO classification of tumors, appendiceal epithelial neoplasms are categorized as follows[1]:
  - Serrated lesions and polyps
  - Mucinous neoplasm
  - Adenocarcinoma
  - GCA
  - Neuroendocrine neoplasms

Background: Appendiceal Mucinous Neoplasms

- There is much ongoing debate over terminology and classification of mucinous neoplasms due to the fact that even low-grade neoplasms can result in pseudomyxomatous peritonei and lack of consensus criteria for invasion into the appendix.
- Current terminology includes low-grade appendiceal mucinous neoplasm (LAMN), high-grade appendiceal mucinous neoplasm (HAMN), low-grade mucinous carcinoma peritonei, high-grade mucinous carcinoma peritonei, and high-grade mucinous carcinoma peritonei with signet ring cells.
- Older terminology that is no longer recommended includes: mucinous tumor of uncertain malignant potential, mucinous cystadenoma of the appendix, borderline tumor of the appendix, mucinous cystadenocarcinoma of the appendix, disseminated peritoneal adenomucinosis, and peritoneal mucinous carcinomatosis with or without signet ring cells.[1,2,3]
- However, some pathologists prefer to use the term "mucinous cystadenoma" to refer to entirely submitted mucinous tumors with no mural or extra-appendiceal mucin. If mural changes are present, such as disruption or atrophy of the muscularis mucosa, these lesions are best classified as LAMN.[4,5]
  - **Low-grade appendiceal mucinous neoplasm (LAMN):**
    - ◊ LAMNs are characterized by tall mucinous epithelial cells in villous or flat arrangement, which invade with a distinct pushing border in contrast to infiltrative glands associated with desmoplasia.
    - ◊ LAMNs are most often associated with atrophy of the appendiceal wall, loss of lymphoid tissue, and effacement of the muscularis mucosa, which can be helpful in differentiating other entities on the histologic differential diagnosis such as ruptured diverticula.[4,5]
    - ◊ Mucin pools are common and can extend into the serosa and beyond.
    - ◊ According to the 9th version of the AJCC, LAMNs confined to the muscularis propria, including acellular mucin or mucinous epithelium, are staged as carcinoma in situ (pTis). pT1 and pT2 are not applicable in LAMN.
    - ◊ Acellular mucin or mucinous epithelium that extends into the subserosa or serosa is classified as pT3 or pT4a, respectively.[6]
    - ◊ LAMNs are almost always microsatellite stable (MSS), *BRAF* V600E negative, and frequently harbor *KRAS* mutations.[2]

References

Note: All recommendations are category 2A unless otherwise indicated.

Version 2.2026, 04/10/26 © 2026 National Comprehensive Cancer Network® (NCCN®), All rights reserved. NCCN Guidelines® and this illustration may not be reproduced in any form without the express written permission of NCCN.

PLEASE NOTE that use of this NCCN Content is governed by the End-User License Agreement, and you MAY NOT distribute this Content or use it with any artificial intelligence model or tool.
Printed by Máximo López Chenlo on 5/4/2026 6:12:29 PM. Copyright © 2026 National Comprehensive Cancer Network, Inc. All Rights Reserved.

PRINCIPLES OF PATHOLOGY AND MOLECULAR REVIEW

- **High-grade appendiceal mucinous neoplasm (HAMN):**
  - ◊ HAMNs retain some similar findings as LAMN but show progression to a more aggressive lesion with the acquisition of high-grade cytologic features and complex architecture.
  - ◊ As such, HAMNs are staged as mucinous adenocarcinomas, although HAMNs are rare and robust data are limited.[2]
- **Mucinous carcinoma peritonei:**
  - ◊ Extra-appendiceal mucin is characterized as acellular or with neoplastic cells that can be low grade, high grade, or high grade with signet ring cells.
  - ◊ The presence or absence of neoplastic cells and the degree of cytologic atypia have prognostic implications in that acellular mucin confined to the right lower quadrant has a low risk of progression whereas mucin with high-grade neoplastic epithelium with signet ring cells is associated with a much worse prognosis.[2,7]
- **Appendiceal adenocarcinoma (AA):**
  - ◊ Outside of LAMN and pseudomyxoma peritonei, other primary AAs are rare and can arise from several distinct precursor lesions such as mucinous neoplasms, intestinal-type adenomas, and GCAs.
  - ◊ These adenocarcinomas often demonstrate abundant extracellular mucin but are distinguished from mucinous neoplasms by a few key differences.
  - ◊ These tumors are highly cellular, have high-grade nuclear features, and show an infiltrative growth pattern with desmoplastic response.[8,9]
  - ◊ Primary mucinous adenocarcinomas are rarely microsatellite unstable (microsatellite instability-high [MSI-H]). However, non-mucinous subtypes have been shown to be MSI-H.[10]
  - ◊ Mucinous subtypes are associated with better outcomes than non-mucinous subtypes. However, higher histologic grade in mucinous subtypes is associated with lower overall 5-year survival rates.[11]
- **Appendiceal goblet cell adenocarcinoma (GCA):**
  - ◊ These tumors have been historically classified as NETs but are now recognized as a distinct clinicopathologic entity with biologic potential more similar to adenocarcinomas than NETs.[9]
  - ◊ Older terminology includes goblet cell carcinoid, goblet cell type adenocarcinoid, mucinous carcinoid, and crypt cell carcinoma.
  - ◊ Microscopically, GCAs are characterized by deep mucosal and submucosal circumferential infiltration without associated surface epithelial dysplasia.
  - ◊ Extension into the muscularis propria and serosa is commonly observed.
  - ◊ GCAs are defined by the presence of a low-grade component comprised of small nests, clusters, and cords of goblet cells. Paneth cells and neuroendocrine cells may be present but are not required for a diagnosis of GCA.
  - ◊ The presence of infiltrating single or small clusters of mucinous or non-mucinous cells, complex cribriform glands, or solid sheets of cells or signet ring cells are evidence of a high-grade component.

References

Note: All recommendations are category 2A unless otherwise indicated.

Version 2.2026, 04/10/26 © 2026 National Comprehensive Cancer Network® (NCCN®), All rights reserved. NCCN Guidelines® and this illustration may not be reproduced in any form without the express written permission of NCCN.

PLEASE NOTE that use of this NCCN Content is governed by the End-User License Agreement, and you MAY NOT distribute this Content or use it with any artificial intelligence model or tool.
Printed by Máximo López Chenlo on 5/4/2026 6:12:29 PM. Copyright © 2026 National Comprehensive Cancer Network, Inc. All Rights Reserved.

PRINCIPLES OF PATHOLOGY AND MOLECULAR REVIEW

- **Appendiceal goblet cell adenocarcinoma (GCA) (continued):**
  - ◊ Recognizing low- and high-grade patterns is critical, as grading GCA depends on the percentages of each component.
    - – Grade 1 and 2 tumors demonstrate >75% and 50%–75% of tubular or clustered growth, respectively.
    - – Grade 3 tumors reveal <50% low-grade pattern and >50% of any combination of the high-grade pattern.[12,13]
  - ◊ As GCAs are often deeply invasive, patients with low-grade histology may present with evidence of metastasis.
  - ◊ Interestingly, GCAs have different molecular profiles from other AAs and neuroendocrine neoplasms in that lower rates of KRAS and APC mutations are consistently reported. However, microsatellite instability (MSI) and high tumor mutational burden (TMB-H) are also rare in these tumors.[14,15]
- **Appendiceal neuroendocrine neoplasms:**
  - ◊ Neuroendocrine neoplasms arising in the appendix include well-differentiated NETs, poorly differentiated neuroendocrine carcinomas (NECs), and MiNENs.[16]
  - ◊ Please see NCCN Guidelines for Neuroendocrine and Adrenal Tumors.

Biomarker Testing

- Biomarker testing, including:
  - *RAS* and *BRAF* V600E mutations; HER2 status; mismatch repair (MMR) or MSI status (if not previously done)
  - Testing should be conducted as part of multigene panel testing (MGPT), which would identify rare and actionable mutations and fusions such as *POLE/POLD1, RET,* and *NTRK* 1/2/3.
  - For more information on biomarker testing, see the Principles of Pathologic and Molecular Review in the NCCN Guidelines for Colon Cancer.

References

Note: All recommendations are category 2A unless otherwise indicated.

Version 2.2026, 04/10/26 © 2026 National Comprehensive Cancer Network® (NCCN®), All rights reserved. NCCN Guidelines® and this illustration may not be reproduced in any form without the express written permission of NCCN.

PLEASE NOTE that use of this NCCN Content is governed by the End-User License Agreement, and you MAY NOT distribute this Content or use it with any artificial intelligence model or tool.
Printed by Máximo López Chenlo on 5/4/2026 6:12:29 PM. Copyright © 2026 National Comprehensive Cancer Network, Inc. All Rights Reserved.

PRINCIPLES OF PATHOLOGY AND MOLECULAR REVIEW
REFERENCES

[1] Nagtegaal ID, Odze RD, Klimstra D, et al. The 2019 WHO classification of tumours of the digestive system. Histopathology 2020;76:182-188.
[2] Carr NJ, Bibeau F, Bradley RF, et al. The histopathological classification, diagnosis and differential diagnosis of mucinous appendiceal neoplasms, appendiceal adenocarcinomas and pseudomyxoma peritonei. Histopathology 2017;71:847-858.
[3] Carr NJ, Cecil TD, Mohamed F, et al. A consensus for classification and pathologic reporting of pseudomyxoma peritonei and associated appendiceal neoplasia: The results for the Peritoneal Surface Oncology Group International (PSOGI) modified Delphi process. Am J Surg Pathol 2016;40:14-26.
[4] Pai RK, Beck AH, Norton JA, et al. Appendiceal mucinous neoplasms: clinicopathologic study of 116 cases with analysis of factors predicting recurrence. Am J Surg Pathol 2009;33:1425-1439.
[5] Misdraji J, Yantiss RK, Graeme-Cook FM, et al. Appendiceal mucinous neoplasms: a clinicopathologic analysis of 107 cases. Am J Surg Pathol 2003;27:1089-1103.
[6] Overman MJ. AJCC Cancer Staging System: Appendix. 9th Version. American College of Surgeons; 2022.
[7] Baratti D, Kusamura S, Milione M, et al. Validation of the recent PSOGI pathologic classification of pseudomyxomatous peritonei in a single-center series of 265 patients treated by cytoreductive surgery and hyperthermic intraperitoneal chemotherapy. Ann Surg Oncol 2018;25:404-413.
[8] Misdraji J, Young RH. Primary epithelial neoplasms and other epithelial lesions of the appendix (excluding carcinoid tumors). Semin Diagn Pathol 2004;21:120-133.
[9] Yantiss RK. Advances in Surgical Pathology: Colorectal Carcinoma and Tumors of the Vermiform Appendix (ed 1). Philadelphia: Lippincott Williams & Wilkins (LWW); 2013:301-312.
[10] Taggart MW, Galbincea J, Mansfield PF, et al. High-level of microsatellite instability in appendiceal carcinomas. Am J Surg Pathol 2013;37:1192-1200.
[11] Asare EA, Compton CC, Hanna NN, et al. The impact of stage, grade, and mucinous histology on the efficacy of systemic chemotherapy in adenocarcinomas of the appendix: Analysis of the National Cancer Data Base. Cancer 2016;122:213-221.
[12] Taggart MW, Abraham SC, Overman MJ, et al. Goblet cell carcinoid tumor, mixed goblet cell carcinoid-adenocarcinoma, and adenocarcinoma of the appendix: comparison of clinicopathologic features and prognosis. Arch Pathol Lab Med 2015;139:782-790.
[13] Yozu M, Johncilla ME, Srivastava A, et al. Histologic and outcome study supports reclassifying appendiceal goblet cell carcinoids as goblet cell adenocarcinomas, and grading and staging similarly to colonic adenocarcinomas. Am J Surg Pathol 2018;42:898-910.
[14] Arai H, Baca Y, Battaglin F, et al. Molecular characterization of appendiceal goblet cell carcinoid. Mol Cancer Ther 2020;19:2634-2640.
[15] Wen KW, Grenert JP, Joseph NM, et al. Genomic profile of appendiceal goblet cell carcinoid is distinct compared to appendiceal neuroendocrine tumor and conventional adenocarcinoma. Hum Pathol 2018;77:166-174.
[16] Volante M, Daniele L, Asioli S, et al. Tumor staging but not grading is associated with adverse clinical outcome in neuroendocrine tumors of the appendix: a retrospective clinical pathologic analysis of 138 cases. Am J Surg Pathol 2013;37:606-612.

Note: All recommendations are category 2A unless otherwise indicated.

Version 2.2026, 04/10/26 © 2026 National Comprehensive Cancer Network® (NCCN®), All rights reserved. NCCN Guidelines® and this illustration may not be reproduced in any form without the express written permission of NCCN.

PLEASE NOTE that use of this NCCN Content is governed by the End-User License Agreement, and you MAY NOT distribute this Content or use it with any artificial intelligence model or tool.
Printed by Máximo López Chenlo on 5/4/2026 6:12:29 PM. Copyright © 2026 National Comprehensive Cancer Network, Inc. All Rights Reserved.

PRINCIPLES OF SURGERY AND CRS/IPCT

- **Localized Disease:**
  - Appendiceal tumors are heterogenous groups of tumors. Knowledge about the different pathologic types is key to appropriate surgical management.
  - Appendiceal tumors are rare but they are more common among patients with complicated appendicitis.
  - Histologies at lower risk of hematogenous spread, including LAMN and HAMN:
    - ◊ Negative margin appendectomy is largely considered to be sufficient. Ileocecectomy may be considered when appendectomy or extended appendectomy is not feasible.
    - ◊ Management of HAMN is controversial with some advocating for right colectomy.
    - ◊ Presence of perforation is a risk factor for peritoneal recurrence and warrants closer surveillance.
  - Histologies at higher risk of hematogenous spread, including adenocarcinoma:
    - ◊ Right hemicolectomy with adequate lymphadenectomy is recommended.
  - There is no clear role for routine second look laparoscopy in the absence of other suggestive risk factors for recurrent disease.

- **Peritoneal Disease:**
  - In cases of incidental peritoneal mucinous or non-mucinous disease during appendectomy or surgical exploration, the focus should be on obtaining a diagnosis rather than extensive resection. Diagnosis can be confirmed by appendectomy and/or biopsy of the most solid- appearing peritoneal implants.
  - Preoperative imaging may underestimate the extent of disease in the peritoneal cavity.
  - Staging laparoscopic exploration may be helpful in estimating the extent of peritoneal disease (PCI) and extent of surgery that will be required.
  - Patients deemed possible surgical candidates should be evaluated and treated by an experienced peritoneal surface malignancy surgeon for candidacy for CRS/IPCT. Expertise in peritoneal resections, multivisceral resections, and organ preservation techniques is key.
    - ◊ Candidacy for CRS/IPCT is determined through a multidisciplinary evaluation of the patient's overall health, disease biology and extent, and tumor resectability.
  - The extent of CRS should be individualized with the focus on optimal cytoreduction with organ preservation.
  - For surgical candidates, optimal cytoreduction (not debulking) with completeness of cytoreduction (CC) score of 0 or 1 is recommended.
  - Mitomycin C is the most commonly used agent for IPCT. Oxaliplatin is another option, but is less preferred, especially in patients who have received or will be receiving IV oxaliplatin.[1,2]
  - Repeat CRS/IPCT may be considered for patients with a history of previous CRS, particularly those with low-grade peritoneal tumors and/or limited peritoneal spread. For high-grade disease, the time since prior surgery should be taken into consideration.
  - In cases where disease is incompletely cytoreduced or resected or CRS is aborted, consider clinical trial, systemic therapy, or best supportive care.

[1] Levine EA, Votanopoulos KI, Shen P, et al. A Multicenter Randomized Trial to Evaluate Hematologic Toxicities after Hyperthermic Intraperitoneal Chemotherapy with Oxaliplatin or Mitomycin in Patients with Appendiceal Tumors. J Am Coll Surg 2018;226:434-443.
[2] Quénet F, Elias D, Roca L, et al. Cytoreductive surgery plus hyperthermic intraperitoneal chemotherapy versus cytoreductive surgery alone for colorectal peritoneal metastases (PRODIGE 7): a multicentre, randomised, open-label, phase 3 trial. Lancet Oncol 2021;22:256-266.

Note: All recommendations are category 2A unless otherwise indicated.

Version 2.2026, 04/10/26 © 2026 National Comprehensive Cancer Network® (NCCN®), All rights reserved. NCCN Guidelines® and this illustration may not be reproduced in any form without the express written permission of NCCN.

PLEASE NOTE that use of this NCCN Content is governed by the End-User License Agreement, and you MAY NOT distribute this Content or use it with any artificial intelligence model or tool.
Printed by Máximo López Chenlo on 5/4/2026 6:12:29 PM. Copyright © 2026 National Comprehensive Cancer Network, Inc. All Rights Reserved.

PRINCIPLES OF SURGERY AND CRS/IPCT

- **No Extraperitoneal Metastasis:**
  - LAMN/HAMN Primary:
    - ◊ The majority of mucinous appendiceal (non-adenocarcinoma) neoplasms are less likely to respond to systemic therapy.
    - ◊ CRS/IPCT is recommended for low-grade (and select high-grade) mucinous tumors.
    - ◊ Optimal cytoreduction should be pursued when possible.
    - ◊ Palliative CRS/IPCT may be considered for unresectable disease in patients who are otherwise surgical candidates.
  - AA/GCA/UC-NOS:
    - ◊ Surgical candidates are suggested to receive perioperative systemic therapy for up to 6 months.
    - ◊ Regular multidisciplinary review is recommended to assess surgical candidacy and optimal timing of surgery, recognizing that patients may have poor response to systemic therapy but still have disease that is amenable to CRS.
    - ◊ Additional systemic therapy may be considered for patients who are not resectable at initial diagnosis with the possibility of converting to resectable disease.
    - ◊ The PCI score and CC score should be reported for cytoreductive surgery.
    - ◊ Surgery is discouraged for high PCI.
    - ◊ If a patient is not a candidate for surgery, treatment should follow metastatic colon cancer guidelines.
- **Extraperitoneal Disease:**
  - Liver surface metastasis (scalloping) is not considered extraperitoneal disease.
  - Management should follow systemic therapy guidelines with palliative measures used as needed for refractory symptoms.
  - Palliative debulking surgery can be considered for disease not responding or poorly responding to systemic therapy, but may be of limited benefit.

Note: All recommendations are category 2A unless otherwise indicated.

Version 2.2026, 04/10/26 © 2026 National Comprehensive Cancer Network® (NCCN®), All rights reserved. NCCN Guidelines® and this illustration may not be reproduced in any form without the express written permission of NCCN.

PLEASE NOTE that use of this NCCN Content is governed by the End-User License Agreement, and you MAY NOT distribute this Content or use it with any artificial intelligence model or tool.
Printed by Máximo López Chenlo on 5/4/2026 6:12:29 PM. Copyright © 2026 National Comprehensive Cancer Network, Inc. All Rights Reserved.

PRINCIPLES OF PALLIATIVE SYSTEMIC THERAPY FOR LAMN OR HAMN[*,a,b,c]

INITIAL THERAPY
• Capecitabine ± Bevacizumab • Fluorouracil/Leucovorin ± Bevacizumab • FOLFIRI (Leucovorin/Fluorouracil/Irinotecan)[d] ± Bevacizumab • FOLFOX (Leucovorin/Fluorouracil/Oxaliplatin)[e] ± Bevacizumab

For AA/GCA/UC-NOS, see APP-D 2 of 11
Footnotes APP-D 3 of 11

[*] Prolonged chemotherapy exposure is not recommended for patients who are not demonstrating a clinical response.

Note: All recommendations are category 2A unless otherwise indicated.

Version 2.2026, 04/10/26 © 2026 National Comprehensive Cancer Network® (NCCN®), All rights reserved. NCCN Guidelines® and this illustration may not be reproduced in any form without the express written permission of NCCN.

PLEASE NOTE that use of this NCCN Content is governed by the End-User License Agreement, and you MAY NOT distribute this Content or use it with any artificial intelligence model or tool.
Printed by Máximo López Chenlo on 5/4/2026 6:12:29 PM. Copyright © 2026 National Comprehensive Cancer Network, Inc. All Rights Reserved.

PRINCIPLES OF PALLIATIVE SYSTEMIC THERAPY FOR AA/GCA/UC-NOS[a,b,c,f]

INITIAL THERAPY

Intensive Therapy Recommended

- CAPEOX (Capecitabine/Oxaliplatin)[e] ± Bevacizumab
- FOLFIRI[d] ± Bevacizumab
- FOLFIRINOX (Leucovorin/Fluorouracil/Irinotecan/Oxaliplatin)[e,g] ± Bevacizumab
- FOLFOX[e] ± Bevacizumab

- *BRAF* V600E mutation positive:
  - FOLFOX[e]/Encorafenib + (Cetuximab or Panitumumab)

Intensive Therapy NOT Recommended

- Capecitabine ± Bevacizumab
- Fluorouracil/Leucovorin ± Bevacizumab

FOR ANY LINE OF THERAPY (if dMMR/MSI-H or *POLE/POLD1* mutation with ultra-hypermutated phenotype [eg, TMB >50 mut/Mb])[h,i,j]

- Cemiplimab-rwlc
- Dostarlimab-gxly
- Ipilimumab + Nivolumab[k]
- Nivolumab[k]
- Pembrolizumab[l]
- Penpulimab-kcqx
- Retifanlimab-dlwr
- Tislelizumab-jsgr
- Toripalimab-tpzi

SECOND-LINE AND SUBSEQUENT THERAPY (if not previously given)

- (FOLFIRI or Irinotecan)[d] ± Bevacizumab
- FOLFIRINOX[e,g] ± Bevacizumab
- (CAPEOX or FOLFOX)[e] ± Bevacizumab
- IROX (Irinotecan[d]/Oxaliplatin[e]) ± Bevacizumab

- For disease that has progressed through all available regimens:
  - Fruquintinib
  - Regorafenib
  - Trifluridine and Tipiracil ± Bevacizumab (Bevacizumab combo preferred)

- Best supportive care (NCCN Guidelines for Palliative Care)

Biomarker-directed therapy

- *BRAF* V600E mutation positive
  - Encorafenib + (Cetuximab or Panitumumab)

- *KRAS* G12C mutation positive
  - (Adagrasib or Sotorasib)[m] + (Cetuximab or Panitumumab)

- HER2-positive and *RAS* and *BRAF* WT
  - (Pertuzumab or Tucatinib)[n] + Trastuzumab[n]

- HER2-positive (IHC 3+)
  - Fam-trastuzumab deruxtecan-nxki[o]

- *NTRK 1/2/3* gene fusion-positive
  - Entrectinib
  - Larotrectinib
  - Repotrectinib[p]

- *RET* gene fusion-positive
  - Selpercatinib

- If *KRAS/NRAS/BRAF* WT[q]:
  - CAPEOX[e] + (Cetuximab or Panitumumab)
  - (Cetuximab or Panitumumab)[r] ± Irinotecan[d]
  - FOLFIRI[d] + (Cetuximab or Panitumumab)[r]
  - FOLFOX[e] + (Cetuximab or Panitumumab)

Footnotes APP-D 3 of 11

Note: All recommendations are category 2A unless otherwise indicated.

Version 2.2026, 04/10/26 © 2026 National Comprehensive Cancer Network® (NCCN®), All rights reserved. NCCN Guidelines® and this illustration may not be reproduced in any form without the express written permission of NCCN.

PLEASE NOTE that use of this NCCN Content is governed by the End-User License Agreement, and you MAY NOT distribute this Content or use it with any artificial intelligence model or tool.
Printed by Máximo López Chenlo on 5/4/2026 6:12:29 PM. Copyright © 2026 National Comprehensive Cancer Network, Inc. All Rights Reserved.

PRINCIPLES OF PALLIATIVE SYSTEMIC THERAPY FOOTNOTES

[a] For systemic therapy references, see Regimens and Dosing (APP-D 4 of 11).
[b] For infection risk, monitoring, and prophylaxis recommendations for targeted therapies, see INF-A in the NCCN Guidelines for Prevention and Treatment of Cancer-Related Infections.
[c] An FDA-approved biosimilar is an appropriate substitute for any recommended systemic biologic therapy in the NCCN Guidelines.
[d] Irinotecan should be used with caution in patients with Gilbert syndrome or elevated serum bilirubin. There is a commercially available test for *UGT1A1*. Guidelines for use in clinical practice have not been established.
[e] Discontinuation of oxaliplatin should be strongly considered after 3 to 4 months of therapy (or sooner for unacceptable neurotoxicity) while maintaining other agents until time of progression. Oxaliplatin may be reintroduced if it was discontinued for neurotoxicity rather than for disease progression.
[f] There is no clear evidence for anti-EGFR therapy, even among *RAS/RAF* WT cancers.
[g] FOLFIRINOX is recommended instead of FOLFOXIRI because FOLFOXIRI uses a high dose of fluorouracil (3,200 mg/m² over 48 hours). Patients in the United States have been shown to have greater toxicity with fluorouracil. The dose of fluorouracil (2,400 mg/m² over 46 hours) is a starting dose consistent with the dose recommended in FOLFOX or FOLFIRI and should be strongly considered for U.S. patients.
[h] NCCN Guidelines for Management of Immunotherapy-Related Toxicities.
[i] If disease response, consider discontinuing checkpoint inhibitor after 2 years of treatment.
[j] If no previous treatment with a checkpoint inhibitor. Nivolumab + ipilimumab may be considered as subsequent therapy if checkpoint inhibitor monotherapy was previously received.
[k] Nivolumab and hyaluronidase-nvhy is not approved for concurrent use with IV ipilimumab; however, for nivolumab monotherapy, nivolumab and hyaluronidase-nvhy subcutaneous injection may be substituted for IV nivolumab. Nivolumab and hyaluronidase-nvhy has different dosing and administration instructions compared to IV nivolumab.
[l] Pembrolizumab and berahyaluronidase alfa-pmph subcutaneous injection may be substituted for IV pembrolizumab. Pembrolizumab and berahyaluronidase alfa-pmph has different dosing and administration instructions compared to IV pembrolizumab.
[m] If patient is unable to tolerate EGFR inhibitor due to toxicity, single-agent adagrasib or sotorasib can be considered.
[n] If no previous treatment with HER2 inhibitor.
[o] Some activity was seen after a previous HER2-targeted regimen. May not be indicated in patients with underlying lung issues due to lung toxicity (3.5% report of drug-related deaths from interstitial lung disease on the DESTINY-CRC01 trial).
[p] On the TRIDENT-1 trial, repotrectinib showed activity in both NTRK TKI-naïve and NTRK TKI-pretreated patients.
[q] Patients with *BRAF* mutations other than V600E may be considered for anti-EGFR therapy.
[r] Cetuximab or panitumumab are recommended in combination with irinotecan-based therapy or as single-agent therapy for patients who cannot tolerate irinotecan.

Note: All recommendations are category 2A unless otherwise indicated.

Version 2.2026, 04/10/26 © 2026 National Comprehensive Cancer Network® (NCCN®), All rights reserved. NCCN Guidelines® and this illustration may not be reproduced in any form without the express written permission of NCCN.

PLEASE NOTE that use of this NCCN Content is governed by the End-User License Agreement, and you MAY NOT distribute this Content or use it with any artificial intelligence model or tool.
Printed by Máximo López Chenlo on 5/4/2026 6:12:29 PM. Copyright © 2026 National Comprehensive Cancer Network, Inc. All Rights Reserved.

PRINCIPLES OF PALLIATIVE SYSTEMIC THERAPY – REGIMENS AND DOSING[c]

Modified FOLFOX6[1,2,3]
Oxaliplatin 85 mg/m² IV Day 1[s]
Leucovorin 400 mg/m² IV Day 1[t]
Fluorouracil 400 mg/m² IV bolus Day 1, followed by 1200 mg/m²/day x 2 days (total 2400 mg/m² over 46–48 hours) IV continuous infusion
Repeat every 2 weeks

Modified FOLFOX7[4]
Oxaliplatin 85 mg/m² IV Day 1[s]
Leucovorin 400 mg/m² IV Day 1[t]
Fluorouracil 1200 mg/m²/day x 2 days (total 2400 mg/m² over 46–48 hours) IV continuous infusion
Repeat every 2 weeks

FOLFOX + Bevacizumab[5,u]
Bevacizumab 5 mg/kg IV Day 1
Repeat every 2 weeks

FOLFOX + Panitumumab[6] (*KRAS/NRAS/BRAF* WT)
Panitumumab 6 mg/kg IV over 60 minutes, Day 1
Repeat every 2 weeks

FOLFOX + Cetuximab[7] (*KRAS/NRAS/BRAF* WT)
Cetuximab 400 mg/m² IV over 2 hours first infusion, followed by 250 mg/m² IV over 60 minutes weekly or Cetuximab 500 mg/m² IV over 2 hours, Day 1, every 2 weeks (preferred for every 2 weeks)

CAPEOX[8]
Oxaliplatin 130 mg/m² IV Day 1[s]
Capecitabine 1000[v] mg/m² twice daily PO for 14 days
Repeat every 3 weeks

CAPEOX + Bevacizumab[8,u]
Oxaliplatin 130 mg/m² IV Day 1[s]
Capecitabine 1000[v] mg/m² PO twice daily for 14 days
Bevacizumab 7.5 mg/kg IV Day 1
Repeat every 3 weeks

CAPEOX + Cetuximab[9-11] (*KRAS/NRAS/BRAF* WT)
Cetuximab 400 mg/m² IV over 2 hours first infusion, followed by 250 mg/m² IV over 60 minutes weekly or Cetuximab 500 mg/m² IV over 2 hours, Day 1, every 2 weeks (preferred for every 2 weeks)

CAPEOX + Panitumumab[9-11] (*KRAS/NRAS/BRAF* WT)
Panitumumab 6 mg/kg IV over 60 minutes, Day 1
Repeat every 2 weeks

FOLFIRI[12,13]
Irinotecan 180 mg/m² IV over 30–90 minutes, Day 1
Leucovorin[t] 400 mg/m² IV infusion to match duration of Irinotecan infusion, Day 1
Fluorouracil 400 mg/m² IV bolus Day 1, followed by 1200 mg/m²/day x 2 days (total 2400 mg/m² over 46–48 hours) continuous infusion
Repeat every 2 weeks

FOLFIRI + Bevacizumab[14,u]
Bevacizumab 5 mg/kg IV Day 1
Repeat every 2 weeks

References

[c] An FDA-approved biosimilar is an appropriate substitute for any recommended systemic biologic therapy in the NCCN Guidelines.
[s] Oxaliplatin may be given either over 2 hours, or may be infused over a shorter time at a rate of 1 mg/m²/min. Leucovorin infusion should match infusion time of oxaliplatin. Cercek A, Park V, Yaeger R, et al. Faster FOLFOX: oxaliplatin can be safely infused at a rate of 1 mg/m²/min. J Oncol Pract 2016;12:e548-553.
[t] Leucovorin 400 mg/m² is the equivalent of levoleucovorin 200 mg/m².
[u] Bevacizumab may be safely given at a rate of 0.5 mg/kg/min (5 mg/kg over 10 minutes and 7.5 mg/kg over 15 minutes).
[v] The majority of safety and efficacy data for this regimen have been developed in Europe, where a capecitabine starting dose of 1000 mg/m² twice daily for 14 days, repeated every 21 days, is standard. Evidence suggests that North American patients may experience greater toxicity with capecitabine (as well as with other fluoropyrimidines) than European patients, and may require a lower dose of capecitabine.

Note: All recommendations are category 2A unless otherwise indicated.

Version 2.2026, 04/10/26 © 2026 National Comprehensive Cancer Network® (NCCN®), All rights reserved. NCCN Guidelines® and this illustration may not be reproduced in any form without the express written permission of NCCN.

PLEASE NOTE that use of this NCCN Content is governed by the End-User License Agreement, and you MAY NOT distribute this Content or use it with any artificial intelligence model or tool.
Printed by Máximo López Chenlo on 5/4/2026 6:12:29 PM. Copyright © 2026 National Comprehensive Cancer Network, Inc. All Rights Reserved.

PRINCIPLES OF PALLIATIVE SYSTEMIC THERAPY – REGIMENS AND DOSING[c]

FOLFIRI + Cetuximab (*KRAS/NRAS/BRAF* WT)
Cetuximab 400 mg/m² IV over 2 hours first infusion, followed by 250 mg/m² IV over 60 minutes weekly[15] or Cetuximab 500 mg/m² IV over 2 hours, Day 1, every 2 weeks[16] (preferred for every 2 weeks)

FOLFIRI + Panitumumab[17](*KRAS/NRAS/BRAF* WT)
Panitumumab 6 mg/kg IV over 60 minutes, Day 1
Repeat every 2 weeks

FOLFIRINOX[18,g]
Oxaliplatin 85 mg/m² IV Day 1,[s] Leucovorin 400 mg/m² IV over 2 hours on Day 1, Irinotecan 165–180 mg/m² IV over 30–90 minutes on Day 1, Fluorouracil 400 mg/m² IV Push Day 1, Fluorouracil 1200 mg/m²/day x 2 days (total 2400 mg/m² over 46 hours) continuous infusion.
Repeat every 2 weeks

Modified FOLFIRINOX[19,20,g]
Oxaliplatin 85 mg/m² IV on Day 1,[s] Leucovorin 400 mg/m² IV over 2 hours on Day 1, Irinotecan 150 mg/m² IV over 30–90 minutes on Day 1, Fluorouracil 1200 mg/m²/day x 2 days (total 2400 mg/m² over 46 hours) continuous infusion. Repeat every 2 weeks

FOLFIRINOX or Modified FOLFIRINOX + Bevacizumab[21,u]
Bevacizumab 5 mg/kg IV Day 1
Repeat every 2 weeks

IROX[22]
Oxaliplatin 85 mg/m² IV,[s]
followed by Irinotecan 200 mg/m² over 30–90 minutes every 3 weeks

IROX + Bevacizumab[u]
Bevacizumab 7.5 mg/kg IV Day 1
Repeat every 3 weeks

Bolus or infusional Fluorouracil/Leucovorin
Roswell Park regimen[23]
Leucovorin 500 mg/m² IV over 2 hours, Days 1, 8, 15, 22, 29, and 36
Fluorouracil 500 mg/m² IV bolus 1 hour after start of Leucovorin, Days 1, 8, 15, 22, 29, and 36
Repeat every 8 weeks

References

[c] An FDA-approved biosimilar is an appropriate substitute for any recommended systemic biologic therapy in the NCCN Guidelines.
[g] FOLFIRINOX is recommended instead of FOLFOXIRI because FOLFOXIRI uses a high dose of fluorouracil (3,200 mg/m² over 48 hours). Patients in the United States have been shown to have greater toxicity with fluorouracil. The dose of fluorouracil (2,400 mg/m² over 46 hours) is a starting dose consistent with the dose recommended in FOLFOX or FOLFIRI and should be strongly considered for U.S. patients.
[s] Oxaliplatin may be given either over 2 hours, or may be infused over a shorter time at a rate of 1 mg/m²/min. Leucovorin infusion should match infusion time of oxaliplatin. Cercek A, Park V, Yaeger R, et al. Faster FOLFOX: oxaliplatin can be safely infused at a rate of 1 mg/m²/min. J Oncol Pract 2016;12:e548-553.
[u] Bevacizumab may be safely given at a rate of 0.5 mg/kg/min (5 mg/kg over 10 minutes and 7.5 mg/kg over 15 minutes).

Note: All recommendations are category 2A unless otherwise indicated.

Version 2.2026, 04/10/26 © 2026 National Comprehensive Cancer Network® (NCCN®), All rights reserved. NCCN Guidelines® and this illustration may not be reproduced in any form without the express written permission of NCCN.

PLEASE NOTE that use of this NCCN Content is governed by the End-User License Agreement, and you MAY NOT distribute this Content or use it with any artificial intelligence model or tool.
Printed by Máximo López Chenlo on 5/4/2026 6:12:29 PM. Copyright © 2026 National Comprehensive Cancer Network, Inc. All Rights Reserved.

PRINCIPLES OF PALLIATIVE SYSTEMIC THERAPY – REGIMENS AND DOSING[c]

Simplified biweekly infusional Fluorouracil/Leucovorin (sLV5FU2)[12]
Leucovorin[t] 400 mg/m² IV over 2 hours on Day 1,
followed by Fluorouracil bolus 400 mg/m² followed by 1200 mg/m²/day x 2 days (total 2400 mg/m² over 46–48 hours) continuous infusion
Repeat every 2 weeks
Weekly
Leucovorin 20 mg/m² IV over 2 hours on Day 1, Fluorouracil 500 mg/m² IV bolus injection 1 hour after the start of Leucovorin. Repeat weekly[24]
or
Fluorouracil 2600 mg/m² by 24-hour infusion plus Leucovorin 500 mg/m²
Repeat every week[24]

Bolus or infusional Fluorouracil + Bevacizumab[u]
Bevacizumab 5 mg/kg IV on Day 1
Repeat every 2 weeks

Capecitabine[25,v]
Capecitabine 850–1250 mg/m² PO twice daily for 14 days
Repeat every 3 weeks

Capecitabine + Bevacizumab[26,u]
Bevacizumab 7.5 mg/kg IV Day 1
Repeat every 3 weeks

Irinotecan
Irinotecan 125 mg/m² IV over 30–90 minutes, Days 1 and 8
Repeat every 3 weeks[27,28]
or Irinotecan 180 mg/m² IV over 30–90 minutes, Day 1
Repeat every 2 weeks
or Irinotecan 300–350 mg/m² IV over 30–90 minutes, Day 1
Repeat every 3 weeks

Irinotecan + Bevacizumab[31,u]
Irinotecan 180 mg/m² IV Day 1
Bevacizumab 5 mg/kg IV Day 1
Repeat every 2 weeks
or
Irinotecan 300–350 mg/m² IV Day 1
Bevacizumab 7.5 mg/kg IV Day 1
Repeat every 3 weeks

Irinotecan + Cetuximab (*KRAS/NRAS/BRAF* WT)
Cetuximab 400 mg/m² first infusion, followed by 250 mg/m² IV weekly[29]
or Cetuximab 500 mg/m² IV over 2 hours, Day 1, every 2 weeks[16]
(preferred for every 2 weeks)

Irinotecan + Panitumumab[17,30] (*KRAS/NRAS/BRAF* WT)
Panitumumab 6 mg/kg IV over 60 minutes every 2 weeks

Cetuximab (*KRAS/NRAS/BRAF* WT)
Cetuximab 400 mg/m² first infusion, followed by 250 mg/m² IV weekly[29]
or Cetuximab 500 mg/m² IV over 2 hours, Day 1, every 2 weeks[16]
(preferred for every 2 weeks)

Panitumumab[32] (*KRAS/NRAS/BRAF* WT)
Panitumumab 6 mg/kg IV over 60 minutes every 2 weeks

Regorafenib
Regorafenib 160 mg PO daily on Days 1–21[33]
or
First cycle: Regorafenib 80 mg PO daily on Days 1–7, followed by 120 mg PO daily on Days 8–14, followed by 160 mg PO daily on Days 15–21[34]
Subsequent cycles: Regorafenib 160 mg PO daily on Days 1–21
Repeat every 28 days

References

[c] An FDA-approved biosimilar is an appropriate substitute for any recommended systemic biologic therapy in the NCCN Guidelines.
[t] Leucovorin 400 mg/m² is the equivalent of levoleucovorin 200 mg/m².
[u] Bevacizumab may be safely given at a rate of 0.5 mg/kg/min (5 mg/kg over 10 minutes and 7.5 mg/kg over 15 minutes).
[v] The majority of safety and efficacy data for this regimen have been developed in Europe, where a capecitabine starting dose of 1000 mg/m² twice daily for 14 days, repeated every 21 days, is standard. Evidence suggests that North American patients may experience greater toxicity with capecitabine (as well as with other fluoropyrimidines) than European patients, and may require a lower dose of capecitabine.

Note: All recommendations are category 2A unless otherwise indicated.

Version 2.2026, 04/10/26 © 2026 National Comprehensive Cancer Network® (NCCN®), All rights reserved. NCCN Guidelines® and this illustration may not be reproduced in any form without the express written permission of NCCN.

PLEASE NOTE that use of this NCCN Content is governed by the End-User License Agreement, and you MAY NOT distribute this Content or use it with any artificial intelligence model or tool.
Printed by Máximo López Chenlo on 5/4/2026 6:12:29 PM. Copyright © 2026 National Comprehensive Cancer Network, Inc. All Rights Reserved.

PRINCIPLES OF PALLIATIVE SYSTEMIC THERAPY – REGIMENS AND DOSING[c]

Trifluridine and Tipiracil ± Bevacizumab[35,36]
Trifluridine and Tipiracil 35 mg/m^2 up to a maximum dose of 80 mg per dose (based on the Trifluridine component)
PO twice daily Days 1–5 and 8–12
Bevacizumab 5 mg/kg on Days 1 and 15
Repeat every 28 days

Pembrolizumab[37] (dMMR/MSI-H or *POLE/POLD1* mutation with ultra-hypermutated phenotype [eg, TMB >50 mut/Mb])
Pembrolizumab 2 mg/kg IV every 3 weeks
or Pembrolizumab 200 mg IV every 3 weeks
or Pembrolizumab 400 mg IV every 6 weeks
or Pembrolizumab 4 mg/kg IV every 6 weeks

Nivolumab[38] (dMMR/MSI-H or *POLE/POLD1* mutation with ultra-hypermutated phenotype [eg, TMB >50 mut/Mb])
Nivolumab 3 mg/kg every 2 weeks
or Nivolumab 240 mg IV every 2 weeks
or Nivolumab 480 mg IV every 4 weeks
or Nivolumab 6 mg/kg IV every 4 weeks

Ipilimumab[39] + Nivolumab (dMMR/MSI-H or *POLE/POLD1* mutation with ultra-hypermutated phenotype [eg, TMB >50 mut/Mb])
Nivolumab 3 mg/kg (30-minute IV infusion) and Ipilimumab 1 mg/kg (30-minute IV infusion) once every 3 weeks for 4 doses, followed by Nivolumab 3 mg/kg IV or Nivolumab 240 mg IV every 2 weeks or Nivolumab 480 mg IV every 4 weeks

Dostarlimab-gxly[40] (dMMR/MSI-H or *POLE/POLD1* mutation with ultra-hypermutated phenotype [eg, TMB >50 mut/Mb])
Dostarlimab-gxly 500 mg IV every 3 weeks for 4 doses followed by 1000 mg IV every 6 weeks

Cemiplimab-rwlc[41,42] (dMMR/MSI-H or *POLE/POLD1* mutation with ultra-hypermutated phenotype [eg, TMB >50 mut/Mb])
350 mg IV on Day 1
Repeat every 3 weeks

Retifanlimab-dlwr[43,44] (dMMR/MSI-H or *POLE/POLD1* mutation with ultra-hypermutated phenotype [eg, TMB >50 mut/Mb])
500 mg IV on Day 1
Repeat every 4 weeks

Tislelizumab-jsgr[45-48] (dMMR/MSI-H or *POLE/POLD1* mutation with ultra-hypermutated phenotype [eg, TMB >50 mut/Mb])
200 mg IV on Day 1
Repeat every 3 weeks

Toripalimab-tpzi[49] (dMMR/MSI-H or *POLE/POLD1* mutation with ultra-hypermutated phenotype [eg, TMB >50 mut/Mb])
3 mg/kg IV on Day 1
Repeat every 2 weeks

Penpulimab-kcqx[50] (dMMR/MSI-H or *POLE/POLD1* mutation with ultra-hypermutated phenotype [eg, TMB >50 mut/Mb])
200 mg IV on Day 1
Repeat every 2 weeks

Pertuzumab[51] + Trastuzumab
(HER2-positive and *RAS* and *BRAF* WT)
Trastuzumab 8 mg/kg IV loading dose on Day 1 of cycle 1, followed by 6 mg/kg IV every 21 days
Pertuzumab 840 mg IV loading dose on Day 1 of cycle 1, followed by 420 mg IV every 21 days

Tucatinib[52] + Trastuzumab
(HER2-positive and *RAS* and *BRAF* WT),
Trastuzumab 8 mg/kg IV loading dose on Day 1 of cycle 1, followed by 6 mg/kg IV every 21 days
Tucatinib 300 mg PO twice daily

Fam-trastuzumab deruxtecan-nxki[53] (HER2-positive, IHC 3+)
Fam-trastuzumab deruxtecan-nxki 5.4 mg/kg IV on Day 1
Repeat every 21 days

References

[c] An FDA-approved biosimilar is an appropriate substitute for any recommended systemic biologic therapy in the NCCN Guidelines.

Note: All recommendations are category 2A unless otherwise indicated.

Version 2.2026, 04/10/26 © 2026 National Comprehensive Cancer Network® (NCCN®), All rights reserved. NCCN Guidelines® and this illustration may not be reproduced in any form without the express written permission of NCCN.

PLEASE NOTE that use of this NCCN Content is governed by the End-User License Agreement, and you MAY NOT distribute this Content or use it with any artificial intelligence model or tool.
Printed by Máximo López Chenlo on 5/4/2026 6:12:29 PM. Copyright © 2026 National Comprehensive Cancer Network, Inc. All Rights Reserved.

PRINCIPLES OF PALLIATIVE SYSTEMIC THERAPY – REGIMENS AND DOSING[c]

Encorafenib + Cetuximab[54-56] (*BRAF* V600E mutation positive)
Encorafenib 300 mg PO daily
Cetuximab 400 mg/m² IV followed by 250 mg/m² IV weekly
or Cetuximab 500 mg/m² IV every 2 weeks

Encorafenib + Panitumumab[54-56](*BRAF* V600E mutation positive)
Encorafenib 300 mg PO daily
Panitumumab 6 mg/kg IV every 14 days

FOLFOX/Encorafenib + Cetuximab[57] (*BRAF* V600E mutation positive)
Encorafenib 300 mg PO daily
Cetuximab 500 mg/m² IV Day 1
Oxaliplatin 85 mg/m² IV Day 1
Leucovorin 400 mg/m² IV Day 1
Fluorouracil 400 mg/m² IV bolus on Day 1, followed by 1200 mg/m²/day x 2 days (total 2400 mg/m² over 46–48 hours) IV continuous infusion
Repeat every 2 weeks

FOLFOX/Encorafenib + Panitumumab[57] (*BRAF* V600E mutation positive)
Encorafenib 300 mg PO daily
Panitumumab 6mg/kg IV every Day 1
Oxaliplatin 85 mg/m² IV Day 1
Leucovorin 400 mg/m² IV Day 1
Fluorouracil 400 mg/m² IV bolus on Day 1, followed by 1200 mg/m²/day x 2 days (total 2400 mg/m² over 46–48 hours) IV continuous infusion
Repeat every 2 weeks

Larotrectinib[58] (*NTRK 1/2/3* gene fusion-positive)
100 mg PO twice daily

Entrectinib[59] (*NTRK 1/2/3* gene fusion-positive)
600 mg PO once daily

Repotrectinib[60] (*NTRK 1/2/3* gene fusion-positive)
160 mg PO daily for first 14 days,
Then increase to 160 mg PO twice daily

Selpercatinib[61] (*RET* gene fusion-positive)
Patients ≥50 kg: 160 mg PO twice daily
Patients <50 kg: 120 mg PO twice daily

Adagrasib + Cetuximab[62] (*KRAS* G12C mutation positive)
Adagrasib 600 mg PO BID
Cetuximab 500 mg/m² IV every 2 weeks

Adagrasib + Panitumumab (*KRAS* G12C mutation positive)
Adagrasib 600 mg PO BID
Panitumumab 6 mg/kg IV every 2 weeks

Sotorasib + Cetuximab (*KRAS* G12C mutation positive)
Sotorasib 960 mg PO daily
Cetuximab 500 mg/m² IV every 2 weeks

Sotorasib + Panitumumab[63] (*KRAS* G12C mutation positive)
Sotorasib 960 mg PO daily
Panitumumab 6 mg/kg IV every 2 weeks

Fruquintinib[64]
5 mg PO daily on Days 1–21
Repeat every 28 days

References

[c] An FDA-approved biosimilar is an appropriate substitute for any recommended systemic biologic therapy in the NCCN Guidelines.

Note: All recommendations are category 2A unless otherwise indicated.

Version 2.2026, 04/10/26 © 2026 National Comprehensive Cancer Network® (NCCN®), All rights reserved. NCCN Guidelines® and this illustration may not be reproduced in any form without the express written permission of NCCN.

PLEASE NOTE that use of this NCCN Content is governed by the End-User License Agreement, and you MAY NOT distribute this Content or use it with any artificial intelligence model or tool.
Printed by Máximo López Chenlo on 5/4/2026 6:12:29 PM. Copyright © 2026 National Comprehensive Cancer Network, Inc. All Rights Reserved.

PRINCIPLES OF PALLIATIVE SYSTEMIC THERAPY – REFERENCES

[1] deGramont A, Figer A, Seymour M, et al. Leucovorin and fluorouracil with or without oxaliplatin as first-line treatment in advanced colorectal cancer. J Clin Oncol 2000;18:2938-2947.
[2] Cheeseman SL, Joel SP, Chester JD, et al. A 'modified de Gramont' regimen of fluorouracil, alone and with oxaliplatin, for advanced colorectal cancer. Br J Cancer 2002;87:393-399.
[3] Maindrault-Goebel F, de Gramont A, Louvet C, et al. Evaluation of oxaliplatin dose intensity in bimonthly leucovorin and 48-hour 5-fluorouracil continuous infusion regimens (FOLFOX) in pretreated metastatic colorectal cancer. Ann Oncol 2000;11:1477-1483.
[4] Hochster HS, Grothey A, Hart L, et al. Improved time to treatment failure with an intermittent oxaliplatin strategy: results of CONcePT. Ann Oncol 2014;25:1172-1178.
[5] Emmanouilides C, Sfakiotaki G, Androulakis N, et al. Front-line bevacizumab in combination with oxaliplatin, leucovorin and 5-fluorouracil (FOLFOX) in patients with metastatic colorectal cancer: a multicenter phase II study. BMC Cancer 2007;7:91.
[6] Douillard JY, Siena S, Cassidy J, et al. Randomized, phase III trial of panitumumab with infusional fluorouracil, leucovorin, and oxaliplatin (FOLFOX4) versus FOLFOX4 alone as first-line treatment in patients with previously untreated metastatic colorectal cancer: the PRIME study. J Clin Oncol 2010;28:4697-4705.
[7] Venook AP, Niedzwiecki D, Lenz HJ, et al. Effect of first-line chemotherapy combined with cetuximab or bevacizumab on overall survival in patients with KRAS wild-type advanced or metastatic colorectal cancer: A randomized clinical trial. JAMA 2017;317:2392-2401.
[8] Saltz LB, Clarke S, Diaz-Rubio E, et al. Bevacizumab in combination with oxaliplatin-based chemotherapy as first-line therapy in metastatic colorectal cancer: a randomized phase III study. J Clin Oncol 2008;26:2013-2019.
[9] Iwamoto S, Maeda H, Hazama S, et al. Efficacy of CapeOX plus cetuximab treatment as a first-line therapy for patients with extended RAS/BRAF/PIK3CA wild-type advanced or metastatic colorectal cancer. J Cancer 2018;9:4092-4098.
[10] Bridgewater JA, Pugh SA, Maishman T, et al. Systemic chemotherapy with or without cetuximab in patients with resectable colorectal liver metastasis (New EPOC): long-term results of a multicentre, randomised, controlled, phase 3 trial. Lancet Oncol 2020;21:398-411.
[11] Maughan TS, Adams RA, Smith CG, et al. Addition of cetuximab to oxaliplatin-based first-line combination chemotherapy for treatment of advanced colorectal cancer: results of the randomised phase 3 MRC COIN trial. Lancet 2011;377:2103-2114.
[12] Andre T, Louvet C, Maindrault-Goebel F, et al. CPT-11 (irinotecan) addition to bimonthly, high-dose leucovorin and bolus and continuous-infusion 5-fluorouracil (FOLFIRI) for pretreated metastatic colorectal cancer. GERCOR. Eur J Cancer 1999;35:1343-1347.
[13] Fuchs CS, Marshall J, Mitchell E, et al. Randomized, controlled trial of irinotecan plus infusional, bolus, or oral fluoropyrimidines in first-line treatment of metastatic colorectal cancer: results from the BICC-C Study. J Clin Oncol 2007;25:4779-4786.
[14] Heinemann V, von Weikersthal LF, Decker T, et al. FOLFIRI plus cetuximab versus FOLFIRI plus bevacizumab as first-line treatment for patients with metastatic colorectal cancer (FIRE-3): a randomized, open-label, phase 3 trial. Lancet Oncol 2014;15:1065-1075.
[15] Cunningham D, Humblet Y, Siena S, et al. Cetuximab monotherapy and cetuximab plus irinotecan in irinotecan-refractory metastatic colorectal cancer. N Engl J Med 2004;351:337-345.
[16] Martín-Martorell P, Roselló S, Rodríguez-Braun E, et al. Biweekly cetuximab and irinotecan in advanced colorectal cancer patients progressing after at least one previous line of chemotherapy: results of a phase II single institution trial. Br J Cancer 2008;99:455-458.
[17] Peeters M, Price TJ, Cervantes A, et al. Randomized phase III study of panitumumab with fluorouracil, leucovorin, and irinotecan (FOLFIRI) compared with FOLFIRI alone as second-line treatment in patients with metastatic colorectal cancer. J Clin Oncol 2010;28:4706-4713.
[18] Conroy T, Bosset J-F, Etienne P-L, et al. Neoadjuvant chemotherapy with FOLFIRINOX and preoperative chemoradiotherapy for patients with locally advanced rectal cancer (UNICANCER-PRODIGE 23): a multicentre, randomised, open-label, phase 3 trial. Lancet Oncol 2021;22:702-715.
[19] Bennouna J, Andre T, Campion L, et al. Rationale and design of the IROCAS study: multicenter, international, randomized phase 3 trial comparing adjuvant modified (m) FOLFIRINOX to mFOLFOX6 in patients with high-risk stage III (pT4 and/or N2) colon cancer-A UNICANCER GI-PRODIGE Trial. Clin Colorectal Cancer 2019;18:e69-e73.
[20] Ychou M, Rivoire M, Thezenas S, et al. A randomized phase II trial of three intensified chemotherapy regimens in first-line treatment of colorectal cancer patients with initially unresectable or not optimally resectable liver metastases. The METHEP Trial. Ann Surg Oncol 2013;20:4289-4297.

Note: All recommendations are category 2A unless otherwise indicated.

Version 2.2026, 04/10/26 © 2026 National Comprehensive Cancer Network® (NCCN®), All rights reserved. NCCN Guidelines® and this illustration may not be reproduced in any form without the express written permission of NCCN.

PLEASE NOTE that use of this NCCN Content is governed by the End-User License Agreement, and you MAY NOT distribute this Content or use it with any artificial intelligence model or tool.
Printed by Máximo López Chenlo on 5/4/2026 6:12:29 PM. Copyright © 2026 National Comprehensive Cancer Network, Inc. All Rights Reserved.

PRINCIPLES OF PALLIATIVE SYSTEMIC THERAPY – REFERENCES

[21] Cremolini C, Loupakis F, Antoniotti C, et al. FOLFOXIRI plus bevacizumab versus FOLFIRI plus bevacizumab as first-line treatment of patients with metastatic colorectal cancer: updated overall survival and molecular subgroup analyses of the open-label, phase 3 TRIBE study. Lancet Oncol 2015;16:1306-1315.
[22] Haller DG, Rothenberg ML, Wong AO, et al. Oxaliplatin plus irinotecan compared with irinotecan alone as second-line treatment after single agent fluoropyrimidine therapy for metastatic colorectal carcinoma. J Clin Oncol 2008;26:4544-4550.
[23] Wolmark N, Rockette H, Fisher B, et al. The benefit of leucovorin-modulated fluorouracil as postoperative adjuvant therapy for primary colon cancer: results from National Surgical Adjuvant Breast and Bowel Protocol C-03. J Clin Oncol 1993;11:1879-1887.
[24] Jäger E, Heike M, Bernhard H, et al. Weekly high-dose leucovorin versus low-dose leucovorin combined with fluorouracil in advanced colorectal cancer: results of a randomized multicenter trial. Study Group for Palliative Treatment of Metastatic Colorectal Cancer Study Protocol 1. J Clin Oncol 1996;14:2274-2279.
[25] Van Cutsem E, Twelves C, Cassidy J, et al. Oral capecitabine compared with intravenous fluorouracil plus leucovorin in patients with metastatic colorectal cancer: results of a large phase III study. J Clin Oncol 2001;19:4097-4106.
[26] Cunningham D, Lang I, Marcuello E, et al. Bevacizumab plus capecitabine versus capecitabine alone in elderly patients with previously untreated metastatic colorectal cancer (AVEX): an open-label, randomised phase 3 trial. Lancet Oncol 2013;14:1077-1085.
[27] Cunningham D, Pyrhonen S, James RD, et al. Randomised trial of irinotecan plus supportive care versus supportive care alone after fluorouracil failure for patients with metastatic colorectal cancer. Lancet 1998;352:1413-1418.
[28] Fuchs CS, Moore MR, Harker G, et al. Phase III comparison of two irinotecan dosing regimens in second-line therapy of metastatic colorectal cancer. J Clin Oncol 2003;21:807-814.
[29] Van Cutsem E, Tejpar S, Vanbeckevoort D, et al. Intrapatient cetuximab dose escalation in metastatic colorectal cancer according to the grade of early skin reactions: the randomized EVEREST study. J Clin Oncol 2012;30:2861-2868.
[30] Andre T, Blons H, Mabro M, et al. Panitumumab combined with irinotecan for patients with KRAS wild-type metastatic colorectal cancer refractory to standard chemotherapy: a GERCOR efficacy, tolerance, and translational molecular study. Ann Oncol 2013;24:412-419.
[31] Yildiz R, Buyukberber S, Uner A, et al. Bevacizumab plus irinotecan-based therapy in metastatic colorectal cancer patients previously treated with oxaliplatin-based regimens. Cancer Invest 2010;28:33-37.
[32] Van Cutsem E, Peeters M, Siena S, et al. Open-label phase III trial of panitumumab plus best supportive care compared with best supportive care alone in patients with chemotherapy-refractory metastatic colorectal cancer. J Clin Oncol 2007;25:1658-1664.
[33] Grothey A, Van Cutsem E, Sobrero A, et al. Regorafenib monotherapy for previously treated metastatic colorectal cancer (CORRECT): an international, multicentre, randomised, placebo-controlled, phase 3 trial. Lancet 2013;381:303-312.
[34] Bekaii-Saab TS, Ou F-S, Ahn DH, et al. Regorafenib-dose optimisation in patients with refractory metastatic colorectal cancer (ReDOS): a randomised, multicentre, open-label, phase 2 study. Lancet Oncol 2019;20:1070-1082.
[35] Mayer RJ, Van Cutsem E, Falcone A, et al. Randomized trial of TAS-102 for refractory metastatic colorectal cancer. N Engl J Med 2015;372:1909-1919.
[36] Prager GW, Taieb J, Fakih M, et al. Trifluridine–tipiracil and bevacizumab in refractory metastatic colorectal cancer. N Engl J Med 2023;388:1657-1667.
[37] Le DT, Uram JN, Wang H, et al. PD-1 blockade in tumors with mismatch-repair deficiency. N Engl J Med 2015;372:2509-2520.
[38] Overman MJ, McDermott R, Leach JL, et al. Nivolumab in patients with metastatic DNA mismatch repair deficient/microsatellite instability-high colorectal cancer (CheckMate 142): results of an open-label, multicentre, phase 2 study. Lancet Oncol 2017;18:1182-1191.
[39] Overman MJ, Lonardi S, Wong KYM, et al. Durable clinical benefit with nivolumab plus ipilimumab in DNA mismatch repair–deficient/microsatellite instability–high metastatic colorectal cancer. J Clin Oncol 2018;36:773-779.
[40] André T, Berton D, Curigliano G, et al. Antitumor activity and safety of dostarlimab monotherapy in patients with mismatch repair deficient solid tumors: A nonrandomized controlled trial. JAMA Netw Open 2023;6:e2341165.
[41] Paccaly AJ, Migden MR, Papadopoulos KP, et al. Fixed dose of cemiplimab in patients with advanced malignancies based on population pharmacokinetic analysis. Adv Ther 2021;38:2365-2378.
[42] Migden MR, Khushalani NI, Chang ALS, et al. Cemiplimab in locally advanced cutaneous squamous cell carcinoma: results from an open-label, phase 2, single-arm trial. Lancet Oncol 2020;21:294-305.

Note: All recommendations are category 2A unless otherwise indicated.

Version 2.2026, 04/10/26 © 2026 National Comprehensive Cancer Network® (NCCN®), All rights reserved. NCCN Guidelines® and this illustration may not be reproduced in any form without the express written permission of NCCN.

PLEASE NOTE that use of this NCCN Content is governed by the End-User License Agreement, and you MAY NOT distribute this Content or use it with any artificial intelligence model or tool.
Printed by Máximo López Chenlo on 5/4/2026 6:12:29 PM. Copyright © 2026 National Comprehensive Cancer Network, Inc. All Rights Reserved.

PRINCIPLES OF PALLIATIVE SYSTEMIC THERAPY – REFERENCES

[43] Berton D, Pautier P, Lorusso D, et al. Antitumor activity and safety of the PD-1 inhibitor retifanlimab in patients with recurrent microsatellite instability-high or deficient mismatch repair endometrial cancer: Final safety and efficacy results from cohort H of the POD1UM-101 phase I study. Gynecol Oncol 2024;186:191-198.
[44] Lakhani N, Cosman R, Banerji U, et al. A first-in-human phase I study of the PD-1 inhibitor, retifanlimab (INCMGA00012), in patients with advanced solid tumors (POD1UM-101). ESMO Open 2024;9:102254.
[45] Li J, Xu Y, Zang A, et al. Tislelizumab in previously treated, locally advanced unresectable/metastatic microsatellite instability-high/mismatch repairdeficient solid tumors. Chin J Cancer Res 2024;36:257-269.
[46] Pang K, Yang Y, Tian D, et al. Long-course chemoradiation plus concurrent/sequential PD-1 blockade as neoadjuvant treatment for MMR-status-unscreened locally advanced rectal cancer: protocol of a multicentre, phase 2, randomised controlled trial (the POLAR-STAR trial). BMJ Open 2023;13:e069499.
[47] Yang Z, Zhang X, Zhang J, et al. Rationale and design of a prospective, multicenter, phase II clinical trial of safety and efficacy evaluation of long course neoadjuvant chemoradiotherapy plus tislelizumab followed by total mesorectal excision for locally advanced rectal cancer (NCRT-PD1-LARC trial). BMC Cancer 2022;22:462.
[48] Zhang L, Geng Z, Hao B, et al. Tislelizumab: A modified anti-tumor programmed death receptor 1 antibody. Cancer Control 2022;29:10732748221111296.
[49] Hu H, Kang PL, Zhang J, et al. Neoadjuvant PD-1 blockade with toripalimab, with or without celecoxib, in mismatch repair-deficient or microsatellite instability-high, locally advanced, colorectal cancer (PICC): a single-centre, parallel-group, non-comparative, randomised, phase 2 trial. Lancet Gastroenterol Hepatol 2022;7:38-48.
[50] Chen X, Wang W, Zou Q, et al. Penpulimab, an anti-PD-1 antibody, for heavily pretreated metastatic nasopharyngeal carcinoma: a single-arm phase II study. Signal Transduct Target Ther 2024;9:148.
[51] Meric-Bernstam F, Hurwitz H, Raghav KPS, et al. Pertuzumab plus trastuzumab for HER2-amplified metastatic colorectal cancer (MyPathway): an updated report from a multicentre, open-label, phase 2a, multiple basket study. Lancet Oncol 2019;20:518-530.
[52] Strickler JH, Cercek A, Siena S, et al. Additional analyses of MOUNTAINEER: A phase II study of tucatinib and trastuzumab for HER2-positive mCRC [abstract]. Ann Oncol 2022;33:S808-S869.
[53] Raghav KPS, Siena S, Takashima A, et al. Trastuzumab deruxtecan (T-DXd) in patients (pts) with HER2-overexpressing/amplified (HER2+) metastatic colorectal cancer (mCRC): Primary results from the multicenter, randomized, phase 2 DESTINY-CRC02 study [abstract]. J Clin Oncol 2023;41(Suppl):Abstract 3501.
[54] Van Cutsem E, Huijberts S, Grothey A, et al. Binimetinib, encorafenib, and cetuximab triplet therapy for patients with *BRAF* V600E-mutant metastatic colorectal cancer: Safety lead-in results from the phase III BEACON colorectal cancer study. J Clin Oncol 2019;37:1460-1469.
[55] Kopetz S, Grothey A, Yaeger R, et al. Encorafenib, binimetinib, and cetuximab in *BRAF* V600E-mutated colorectal cancer. N Engl J Med 2019;381:1632-1643.
[56] Kopetz S, Grothey A, Van Cutsem E, et al. Quality of life with encorafenib plus cetuximab with or without binimetinib treatment in patients with BRAF V600E-mutant metastatic colorectal cancer: patient-reported outcomes from BEACON CRC. ESMO Open 2022;7:100477.
[57] Kopetz S, Yoshino T, Cutsem EV, et al. Encorafenib, cetuximab and chemotherapy in BRAF-mutant colorectal cancer: a randomized phase 3 trial. Nat Med 2025;31:901-908.
[58] Drilon A, Laetsch TW, Kummar S, et al. Efficacy of larotrectinib in TRK fusion-positive cancers in adults and children. N Engl J Med 2018;378:731-739.
[59] Doebele RC, Drilon A, Paz-Ares L, et al. Entrectinib in patients with advanced or metastatic NTRK fusion-positive solid tumours: integrated analysis of three phase 1-2 trials. Lancet Oncol 2020;21:271-282.
[60] Solomon BJ, Drilon A, Lin JJ, et al. 1372P Repotrectinib in patients (pts) with NTRK fusion-positive (NTRK+) advanced solid tumors, including NSCLC: Update from the phase I/II TRIDENT-1 trial [abstract]. Ann Oncol 2023;34:S787-S788.
[61] Subbiah V, Wolf J, Konda B, et al. Tumour-agnostic efficacy and safety of selpercatinib in patients with RET fusion-positive solid tumours other than lung or thyroid tumours (LIBRETTO-001): a phase 1/2, open-label, basket trial. Lancet Oncol 2022;23:1261-1273.
[62] Yaeger R, Weiss J, Pelster M, et al. Adagrasib with or without cetuximab in colorectal cancer with mutated KRAS G12C. N Engl J Med 2023;388:44-54.
[63] Kuboki Y, Yaeger R, Fakih MG, et al. 45MO Sotorasib in combination with panitumumab in refractory KRAS G12C-mutated colorectal cancer: Safety and efficacy for phase Ib full expansion cohort [abstract]. Ann Oncol 2022;33:S136-S196.
[64] Dasari A , Lonardi S, Garcia-Carbonero R, et al. Fruquintinib versus placebo in patients with refractory metastatic colorectal cancer (FRESCO-2): an international, multicentre, randomised, double-blind, phase 3 study. Lancet 2023;402:41-53.

Note: All recommendations are category 2A unless otherwise indicated.

Version 2.2026, 04/10/26 © 2026 National Comprehensive Cancer Network® (NCCN®), All rights reserved. NCCN Guidelines® and this illustration may not be reproduced in any form without the express written permission of NCCN.

PLEASE NOTE that use of this NCCN Content is governed by the End-User License Agreement, and you MAY NOT distribute this Content or use it with any artificial intelligence model or tool.
Printed by Máximo López Chenlo on 5/4/2026 6:12:29 PM. Copyright © 2026 National Comprehensive Cancer Network, Inc. All Rights Reserved.

PRINCIPLES OF SURVIVORSHIP

Surveillance

- Surveillance recommendations can be found on APP-6 and APP-8.
- Long-term surveillance should be carefully managed with routine good medical care and monitoring, including cancer screening, routine health care, and preventive care.
- Routine CEA monitoring and routine CT scanning are not recommended beyond 5 years for high-risk disease. For low-risk disease, routine CEA monitoring and routine CT scanning are not recommended beyond 10 years.

Survivorship Care Planning

The oncologist and primary care provider should have defined roles in the surveillance period, with roles communicated to the patient.[1]

- Develop survivorship care plan that includes:
  - Overall summary of treatment, including all surgeries, radiation treatments, and systemic therapy received.
  - Description of possible expected time to resolution of acute toxicities, long-term effects of treatment, and possible late sequelae of treatment.
  - Surveillance recommendations.
  - Delineation of appropriate timing of transfer of care with specific responsibilities identified for primary care physician and oncologist.
  - Health behavior recommendations.
  - Fertility counseling.

Management of Late/Long-Term Sequelae of Disease or Treatment[2-6]

- For issues related to distress, pain, neuropathy, fatigue, or sexual dysfunction, see NCCN Guidelines for Survivorship.
- For chronic diarrhea or incontinence:
  - Consider anti-diarrheal agents, bulk-forming agents, diet manipulation, pelvic floor rehabilitation, and protective undergarments.
- Management of an ostomy:
  - Consider participation in an ostomy support group or coordination of care with a health care provider specializing in ostomy care (ie, ostomy nurse).
  - Screen for distress around body changes (NCCN Guidelines for Distress Management) and precautions around involvement with physical activity (see page SPA-C in the NCCN Guidelines for Survivorship).
- For oxaliplatin-induced neuropathy:
  - Consider duloxetine for painful neuropathy only, not effective for numbness, tingling, or cold sensitivity.[7]
  - Consider non-pharmacologic therapies such as heat or acupuncture.
  - Pregabalin or gabapentin are not recommended.

Counseling Regarding Healthy Lifestyle and Wellness[8]

(NCCN Guidelines for Survivorship)

- Undergo all age- and gender-appropriate cancer and preventive health screenings as per national guidelines.
- Maintain a healthy body weight throughout life.
- Adopt a physically active lifestyle (at least 30 minutes of moderate-intensity activity on most days of the week). Activity recommendations may require modification based on treatment sequelae (ie, ostomy, neuropathy).
- Consume a healthy diet with emphasis on plant sources. Diet recommendations may be modified based on severity of bowel dysfunction.
- Drink alcohol sparingly, if at all.
- Receive smoking cessation counseling as appropriate (NCCN Guidelines for Smoking Cessation).

Additional health monitoring and immunizations should be performed as indicated under the care of a primary care physician. Survivors are encouraged to maintain a therapeutic relationship with a primary care physician throughout their lifetime.

References

Note: All recommendations are category 2A unless otherwise indicated.

Version 2.2026, 04/10/26 © 2026 National Comprehensive Cancer Network® (NCCN®), All rights reserved. NCCN Guidelines® and this illustration may not be reproduced in any form without the express written permission of NCCN.

PLEASE NOTE that use of this NCCN Content is governed by the End-User License Agreement, and you MAY NOT distribute this Content or use it with any artificial intelligence model or tool.
Printed by Máximo López Chenlo on 5/4/2026 6:12:29 PM. Copyright © 2026 National Comprehensive Cancer Network, Inc. All Rights Reserved.

PRINCIPLES OF SURVIVORSHIP – REFERENCES

[1] Hewitt M, Greenfield S, Stovall E. From Cancer Patient to Cancer Survivor: Lost in Transition. Washington, D.C.:The National Academies Press; 2006.
[2] Schneider EC, Malin JL, Kahn KL, et al. Surviving colorectal cancer: patient-reported symptoms 4 years after diagnosis. Cancer 2007;110:2075-2082.
[3] Sprangers MAG, Taal BG, Aaronson NK, et al. Quality of life in colorectal cancer. Stoma vs. nonstoma patients. Dis Colon Rectum 1995;38:361-369.
[4] Gami B, Harrington K, Blake P, et al. How patients manage gastrointestinal symptoms after pelvic radiotherapy. Aliment Pharmacol Ther 2003;18:987-994.
[5] DeSnoo L, Faithfull S. A qualitative study of anterior resection syndrome: the experiences of cancer survivors who have undergone resection surgery. Eur J Cancer 2006;15:244-251.
[6] McGough C, Baldwin C, Frost C, et al. Role of nutritional intervention in patients treated with radiotherapy for pelvic malignancy. Br J Cancer 2004;90:2278-2287.
[7] Lavoie Smith EM, Pang H, Cirrincione C, et al. Effect of duloxetine on pain, function, and quality of life among patients with chemotherapy-induced painful peripheral neuropathy. JAMA 2013;309:1359-1367.
[8] Kushi LH, Byers T, Doyle C, et al and The American Cancer Society 2006 Nutrition and Physical Activity Guidelines Advisory Committee. American Cancer Society Guidelines on Nutrition and Physical Activity for cancer prevention: Reducing the risk of cancer with healthy food choices and physical activity. CA Cancer J Clin 2006;56:254-281.

Note: All recommendations are category 2A unless otherwise indicated.

Version 2.2026, 04/10/26 © 2026 National Comprehensive Cancer Network® (NCCN®), All rights reserved. NCCN Guidelines® and this illustration may not be reproduced in any form without the express written permission of NCCN.

PLEASE NOTE that use of this NCCN Content is governed by the End-User License Agreement, and you MAY NOT distribute this Content or use it with any artificial intelligence model or tool.
Printed by Máximo López Chenlo on 5/4/2026 6:12:29 PM. Copyright © 2026 National Comprehensive Cancer Network, Inc. All Rights Reserved.

American Joint Committee on Cancer (AJCC) TNM Staging Classification for Appendix Cancer 9th ed., 2022

Table 1. **Definitions for T, N, M**

T	**Primary Tumor**
TX	Primary tumor cannot be assessed
T0	No evidence of primary tumor
Tis	Carcinoma *in situ* (intramucosal carcinoma; invasion of the lamina propria or extension into but not through the muscularis mucosae)
Tis(LAMN)	Low-grade appendiceal mucinous neoplasm confined to the muscularis propria; Acellular mucin or mucinous epithelium may invade into the muscularis propria T1 and T2 are not applicable to LAMN; Acellular mucin or mucinous epithelium that extends into the subserosa or serosa should be classified as T3 or T4a, respectively
T1	Tumor invades the submucosa (through the muscularis mucosa but not into the muscularis propria)
T2	Tumor invades the muscularis propria
T3	Tumor invades through the muscularis propria into the subserosa or the mesoappendix
T4	Tumor invades the visceral peritoneum, including acellular mucin or mucinous epithelium involving the serosa of the appendix or mesoappendix, and/or directly invades adjacent organs or structures
T4a	Tumor invades the visceral peritoneum, including acellular mucin or mucinous epithelium involving the serosa of the appendix or serosa of the mesoappendix
T4b	Tumor directly invades or adheres to adjacent organs or structures

N	**Regional Lymph Nodes**
NX	Regional lymph nodes cannot be assessed
N0	No tumor involvement of regional lymph node(s)
N1	Tumor involvement of one to three regional lymph nodes (tumor in lymph node measuring greater than or equal to 0.2 mm) or any number of tumor deposits is present with no tumor involvement in all identifiable lymph nodes
N1a	Tumor involvement of one regional lymph node
N1b	Tumor involvement of two or three regional lymph nodes
N1c	No tumor involvement of regional lymph nodes, but there are tumor deposits in the subserosa or mesentery
N2	Tumor involvement of four or more regional lymph nodes

M	**Distant Metastasis**
cM0	No distant metastasis
cM1	Distant metastasis
cM1c	Metastasis to sites other than peritoneum
pM1	Microscopic confirmation of distant metastasis
pM1a	Intraperitoneal acellular mucin, without identifiable tumor cells in the disseminated peritoneal mucinous deposits
pM1b	Intraperitoneal metastasis only, including peritoneal mucinous deposits containing tumor cells
pM1c	Microscopic confirmation of metastasis to sites other than peritoneum

Note: For specimens containing acellular mucin without identifiable tumor cells, efforts should be made to obtain additional tissue for thorough histologic examination to evaluate for cellularity.

©, 2021, American College of Surgeons, All Rights Reserved. *Used with permission of the American College of Surgeons, Chicago, Illinois. The original source for this information is the AJCC Cancer Staging System.*

Version 2.2026, 04/10/26 © 2026 National Comprehensive Cancer Network® (NCCN®), All rights reserved. NCCN Guidelines® and this illustration may not be reproduced in any form without the express written permission of NCCN.

PLEASE NOTE that use of this NCCN Content is governed by the End-User License Agreement, and you MAY NOT distribute this Content or use it with any artificial intelligence model or tool.
Printed by Máximo López Chenlo on 5/4/2026 6:12:29 PM. Copyright © 2026 National Comprehensive Cancer Network, Inc. All Rights Reserved.

American Joint Committee on Cancer (AJCC)
TNM Staging System for Appendix Cancer 9th ed., 2022

Table 2. **Prognostic Groups**

	T	N	M
Stage 0	Tis	N0	M0
Stage 0	Tis(LAMN)		
Stage I	T1, T2	N0	M0
Stage IIA	T3	N0	M0
Stage IIB	T4a	N0	M0
Stage IIC	T4b	N0	M0
Stage IIIA	T1-T2	N1	M0
Stage IIIB	T3-T4	N1	M0
Stage IIIC	Any T	N2	M0
Stage IVA	Any T	Any N	M1a-M1b
Stage IVB	Any T	Any N	M1b
Stage IVC	Any T	Any N	M1c

©, 2021, American College of Surgeons, All Rights Reserved. *Used with permission of the American College of Surgeons, Chicago, Illinois. The original source for this information is the AJCC Cancer Staging System.*

Version 2.2026, 04/10/26 © 2026 National Comprehensive Cancer Network® (NCCN®), All rights reserved. NCCN Guidelines® and this illustration may not be reproduced in any form without the express written permission of NCCN.

PLEASE NOTE that use of this NCCN Content is governed by the End-User License Agreement, and you MAY NOT distribute this Content or use it with any artificial intelligence model or tool.
Printed by Máximo López Chenlo on 5/4/2026 6:12:29 PM. Copyright © 2026 National Comprehensive Cancer Network, Inc. All Rights Reserved.

ABBREVIATIONS

A/P	abdomen/pelvis
AA	appendiceal adenocarcinoma
C/A/P	chest/abdomen/pelvis
CBC	complete blood count
CC	completeness of cytoreduction
CEA	carcinoembryonic antigen
CMP	comprehensive metabolic panel
CRS	cytokine release syndrome
ctDNA	circulating tumor DNA
dMMR	mismatch repair deficient
FDG	fluorodeoxyglucose
GBCA	gadolinium-based contrast agent
GCA	goblet-cell adenocarcinoma
HAMN	high-grade appendiceal mucinous neoplasm
IHC	immunohistochemistry
IPCT	intraperitoneal chemotherapy
LAMN	low-grade appendiceal mucinous neoplasm
MGPT	multigene panel testing
MiNEN	mixed neuroendocrine-nonneuroendocrine neoplasm
MMR	mismatch repair
MSI	microsatellite instability
MSI-H	microsatellite instability-high
MSS	microsatellite stable
MWA	microwave ablation
mut/Mb	mutations/megabase
NET	neuroendocrine tumor
NOS	not otherwise specified
PCI	Peritoneal Cancer Index
PNI	perineural invasion
RFA	radiofrequency ablation
SBRT	stereotactic body radiation therapy
TMB	tumor mutational burden
UC	undifferentiated carcinoma
WT	wild-type

Version 2.2026, 04/10/26 © 2026 National Comprehensive Cancer Network® (NCCN®), All rights reserved. NCCN Guidelines® and this illustration may not be reproduced in any form without the express written permission of NCCN.

PLEASE NOTE that use of this NCCN Content is governed by the End-User License Agreement, and you MAY NOT distribute this Content or use it with any artificial intelligence model or tool.
Printed by Máximo López Chenlo on 5/4/2026 6:12:29 PM. Copyright © 2026 National Comprehensive Cancer Network, Inc. All Rights Reserved.

NCCN Categories of Evidence and Consensus	
Category 1	Based upon high-level evidence (≥1 randomized phase 3 trials or high-quality, robust meta-analyses), there is uniform NCCN consensus (≥85% support of the Panel) that the intervention is appropriate.
Category 2A	Based upon lower-level evidence, there is uniform NCCN consensus (≥85% support of the Panel) that the intervention is appropriate.
Category 2B	Based upon lower-level evidence, there is NCCN consensus (≥50%, but <85% support of the Panel) that the intervention is appropriate.
Category 3	Based upon any level of evidence, there is major NCCN disagreement that the intervention is appropriate.

All recommendations are category 2A unless otherwise indicated.

NCCN Categories of Preference	
Preferred	Interventions that are based on superior efficacy, safety, and evidence; and, when appropriate, affordability.
Other recommended	Other interventions that may be somewhat less efficacious, more toxic, or based on less mature data; or significantly less affordable for similar outcomes.
Useful in certain circumstances	Other interventions that may be used for selected patient populations (defined with recommendation).

All recommendations are considered appropriate.

PLEASE NOTE that use of this NCCN Content is governed by the End-User License Agreement, and you MAY NOT distribute this Content or use it with any artificial intelligence model or tool.
Printed by Máximo López Chenlo on 5/4/2026 6:12:29 PM. Copyright © 2026 National Comprehensive Cancer Network, Inc. All Rights Reserved.

Discussion

This discussion corresponds to the NCCN Guidelines for Appendiceal Neoplasms and Cancers. Last updated: April 10, 2026.

Table of Contents

Overview MS-2
Guidelines Update Methodology MS-2
Literature Search Criteria MS-2
Sensitive/Inclusive Language Usage MS-3
Risk Assessment MS-3
Clinical Presentation & Workup MS-3
Pathology & Molecular Classification MS-4
- Appendiceal Serrated Lesions and Polyps MS-4
- Appendiceal Mucinous Neoplasms MS-5
- Appendiceal Adenocarcinoma (AA) MS-6
- Goblet Cell Adenocarcinoma MS-7
- Mucinous Carcinoma Peritonei (Pseudomyxoma Peritonei) MS-7
- Appendiceal Neuroendocrine Neoplasms MS-8
- Targeted Therapy and Appendiceal Neoplasms MS-8

Imaging MS-8
- Computed Tomography (CT) Scan MS-8
- FDG-PET/CT MS-9
- MRI MS-9
- Diagnostic Laparoscopy MS-9
- Image-Guided Biopsy MS-9

Surgical Resection MS-10
- Appendectomy MS-10
- Cecal Cuff Resection MS-11
- Right Hemicolectomy (RHC) MS-11
- Lymph Node Dissection MS-12
- Treatment of Peritoneal Metastasis MS-12

Systemic Therapy for Resectable Disease MS-16
- Neoadjuvant Chemotherapy MS-16
- Adjuvant Chemotherapy MS-17

Palliative Systemic Therapy for Advanced or Metastatic Disease MS-18
- Systemic Therapy for LAMN or HAMN MS-18
- Systemic Therapy for Appendiceal Carcinomas (AA, GCA, or UC-NOS) MS-19

Post-Treatment Surveillance MS-20
Survivorship MS-21
Summary MS-22
References MS-23

Version 2.2026 © 2026 National Comprehensive Cancer Network© (NCCN©), All rights reserved. NCCN Guidelines® and this illustration may not be reproduced in any form without the express written permission of NCCN.

PLEASE NOTE that use of this NCCN Content is governed by the End-User License Agreement, and you MAY NOT distribute this Content or use it with any artificial intelligence model or tool.
Printed by Máximo López Chenlo on 5/4/2026 6:12:29 PM. Copyright © 2026 National Comprehensive Cancer Network, Inc. All Rights Reserved.

Overview

Appendiceal cancers (AC) and appendiceal neoplasms comprise a spectrum of rare tumors of the digestive system often found incidentally on surgical specimens following appendectomy for presumed acute appendicitis. Malignant tumors of the appendix are confirmed by pathologic review in 0.9% to 1.4% of all appendectomy specimens and 0.4% of all confirmed gastrointestinal (GI) cancers.[1,2] An epidemiologic study put the age-adjusted incidence of AC at 0.12 cases per 1,000,000 people per year,[3] although other studies have put incidence rates between 0.63 to 0.97 per 100,000 people.[4]

Although primary appendiceal malignancies are still considered rare, several studies have pointed towards a recent increase in incidence rates.[4-6] Between 2000 and 2016 the incidence rate increased by 232% in the United States, while rates of appendicectomies remained the same, suggesting that the rise in AC is not directly related to an increase in incidental tumors.[5] In a study comparing trends in AC with right-sided colon cancers from 2004 to 2017, out of 387,867 patients with right-sided colon cancer (including appendiceal), approximately 5% had AC and the odds of AC, relative to right-sided colon cancer, increased over time, most markedly in patients between 40 to 49 years of age.[7] A 2025 study comparing incidence rates of AC across different birth cohorts found that they more than tripled among the 1980 birth cohort and quadrupled among the 1985 birth cohort, when compared with the 1945 birth cohort.[6] These increases were noted for all histologic tumor types.

Historically, diagnosing appendix cancer has been difficult due to non-specific early onset of symptoms, lack of clinical or pathologic understanding leading to misdiagnosis, low incidence rates and small sample sizes resulting in low-quality data, and differentiating diagnosis of ovarian adnexal-derived tumors.[8] Unfortunately, due to the rarity and heterogeneity of the disease, few clinical advancements have been made in the last decade; although, it is well known that histologic subtype in addition to tumor grade and stage have been strongly attributed to variations in survival outcomes.[9,10]

The NCCN Panel's recommendations for management of appendiceal tumors were previously included within the NCCN Clinical Practice Guidelines in Oncology (NCCN Guidelines®) for Colon Cancer, with few recommendations specific to AC. These NCCN Guidelines® for Appendiceal Neoplasms and Cancers represent the NCCN Panel's acknowledgement of AC as a unique entity with a spectrum of histologic subtypes requiring specific recommendations for treatment. Concurrent to this, there have been several large efforts to create independent guidelines, notably the Chicago Consensus Working Group and Peritoneal Surface Malignancies Consortium Group.[11-13] The NCCN Guidelines begin with the clinical presentation of the patient and address diagnosis, histopathologic evaluation, pathologic staging, surgical management, systemic therapy, surveillance, management of recurrent and metastatic disease, and survivorship. Although these guidelines are believed to represent the optimal treatment strategy, participation in a clinical trial, when available, is especially encouraged for patients with AC based on the lack of clinical trial data on which to base treatment decisions.

Guidelines Update Methodology

The complete details of the Development and Update of the NCCN Guidelines are available at www.NCCN.org.

Literature Search Criteria

Prior to the update of the NCCN Guidelines for Appendiceal Neoplasms and Cancers, an electronic search of the PubMed database was performed to obtain key literature in the field of appendiceal neoplasms and cancers published within the previous decade, using the following search terms: appendiceal adenocarcinoma, appendiceal neoplasm,

Version 2.2026 © 2026 National Comprehensive Cancer Network© (NCCN©), All rights reserved. NCCN Guidelines® and this illustration may not be reproduced in any form without the express written permission of NCCN.

PLEASE NOTE that use of this NCCN Content is governed by the End-User License Agreement, and you MAY NOT distribute this Content or use it with any artificial intelligence model or tool.
Printed by Máximo López Chenlo on 5/4/2026 6:12:29 PM. Copyright © 2026 National Comprehensive Cancer Network, Inc. All Rights Reserved.

appendix cancer, pseudomyxoma peritonei, low-grade appendiceal mucinous neoplasms (LAMN), high-grade appendiceal mucinous neoplasms (HAMN). The PubMed database was chosen as it remains the most widely used resource for medical literature and indexes peer-reviewed biomedical literature.[14]

The search results were narrowed by selecting studies in humans published in English. Results were confined to the following article types: Clinical Trial, Phase II; Clinical Trial, Phase III; Clinical Trial, Phase IV; Guideline; Practice Guideline; Randomized Controlled Trial; Meta-Analysis; Systematic Reviews; and Validation Studies. The data from key PubMed articles as well as articles from additional sources deemed as relevant to these Guidelines as discussed by the Panel during the Guidelines update have been included in this version of the Discussion section. Recommendations for which high-level evidence is lacking are based on the Panel's review of lower-level evidence and expert opinion.

Sensitive/Inclusive Language Usage

NCCN Guidelines strive to use language that advances the goals of equity, inclusion, and representation.[15] NCCN Guidelines endeavor to use language that is person-first; not stigmatizing; anti-racist, anti-classist, anti-misogynist, anti-ageist, anti-ableist, and anti-weight-biased; and inclusive of individuals of all sexual orientations and gender identities. NCCN Guidelines incorporate non-gendered language, instead focusing on organ-specific recommendations. This language is both more accurate and more inclusive and can help fully address the needs of individuals of all sexual orientations and gender identities. NCCN Guidelines will continue to use the terms *men*, *women*, *female*, and *male* when citing statistics, recommendations, or data from organizations or sources that do not use inclusive terms. Most studies do not report how sex and gender data are collected and use these terms interchangeably or inconsistently. If sources do not differentiate gender from sex assigned at birth or organs present, the information is presumed to predominantly represent cisgender individuals. NCCN encourages researchers to collect more specific data in future studies and organizations to use more inclusive and accurate language in their future analyses.

Risk Assessment

According to the National Cancer Database (NCDB), out of 11,799 people diagnosed with AC, 55.3% were female, 77.9% were non-Hispanic white, 9.5% were non-Hispanic Black, 6.0% were Hispanic, and 2.5% were Asian/Pacific Islanders.[16] In 2021, a study compared trends in histologic subtype, tumor grade, stage, sex, and ethnicity in 8851 individuals diagnosed with AC.[10] The individuals in this study were in the United States between years 2007 to 2016 and were at least 20 years of age at primary AC diagnosis. Out of the total number of participants, 30.8% were diagnosed before 50 years of age. Patients diagnosed with early-onset AC (≤50 years of age) were 82% more likely to be Hispanic, American Indian, or Alaskan Native compared to patients diagnosed at >50 years of age.[10] In contrast, the overall incidence rate in those who were white and Black generally was the same across all ages.[17,18] Patients with early-onset AC were also more likely to be diagnosed with neuroendocrine tumors (NETs) in addition to early-onset tumors being 45% to 61% less likely to be pathologically diagnosed as stage (III–IV) high-grade tumors.[5,10] Data also suggest that intestinal NETs, including those of the appendix, have a higher incidence rate in individuals effected by obesity (body mass index [BMI]:30+ kg/m^2).[19]

Clinical Presentation & Workup

Patients may present with symptoms resembling appendicitis, which include but are not limited to: abdominal pain in the right lower quadrant, vomiting, change in bowel habits, intestinal obstruction, compression of the ureters, and nausea.[17,20-22] There should be increased suspicion of an appendiceal neoplasm if the patient is >50 years of age with a family

Version 2.2026 © 2026 National Comprehensive Cancer Network© (NCCN©), All rights reserved. NCCN Guidelines® and this illustration may not be reproduced in any form without the express written permission of NCCN.

PLEASE NOTE that use of this NCCN Content is governed by the End-User License Agreement, and you MAY NOT distribute this Content or use it with any artificial intelligence model or tool.
Printed by Máximo López Chenlo on 5/4/2026 6:12:29 PM. Copyright © 2026 National Comprehensive Cancer Network, Inc. All Rights Reserved.

history of inflammatory bowel disease, colon cancer, and/or unexplained anemia.[23] Additionally, if appendicitis is treated nonoperatively (typically with antibiotics), repeat interval imaging is crucial to ensure that the imaging findings resolve. Lack of resolution may suggest an appendiceal malignancy.

Diagnosing neoplasms of the appendix is challenging and symptoms may overlap with colon cancer, gynecologic cancers, or other abdominal pathologies. Diagnostic tests at initial presentation include CT imaging, diagnostic laparoscopy or image-guided biopsy, and in some cases surgery, in addition to a thorough medical history and physical examination, including complete blood count (CBC) and comprehensive metabolic panel (CMP).[24] An appendix >15 mm on a CT or MRI with an irregular or thickened wall is suggestive of AC.[25] Non-specific abdominal bloating/distention and/or postprandial discomfort may also be observed with mucinous peritoneal involvement. Colonoscopy is recommended to rule out other primary lesions, although it may be done concurrently with other diagnostic tests and should not delay treatment.[25,26] A negative colonoscopy does not rule out an appendix primary lesion, as distal primaries are typically unable to be seen luminally. If the diagnosis is reached postoperatively, a thorough review of operative notes and pathology slides is encouraged in order to rule out more aggressive disease and other findings such as presence of perforation, ascites, extent of peritoneal spread, and/or the presence of extracellular mucin.

Several studies have investigated the use of tumor markers, including carcinoembryonic antigen (CEA), CA 19-9, and CA-125, for prognostication of appendiceal neoplasms and cancers. In one such study, a multivariate analysis concluded that when CA 19-9 was elevated preoperatively, progression-free survival (PFS) was unfavorable. Additionally, when CEA was elevated preoperatively, overall survival (OS) was also unfavorable.[27] CA-125 level was inconclusive in this study; however, other studies suggest normal serum levels of CA-125 and CA 19-9 correspond to an increase in survival and a decrease in recurrence.[28] Similarly, a retrospective cohort study of 1338 patients with appendiceal adenocarcinoma (AA) found that elevations of CEA, CA 19-9, or CA-125 were associated with worse 5-year survival, and patients with highly elevated (top 10th percentile) markers had markedly worse survival outcomes.[29] Therefore, it is recommended to measure CEA, CA 19-9, and CA-125 marker levels as part of initial workup.

Upon confirmation of appendiceal neoplasms or cancer, fertility risk discussion and counseling are recommended in appropriate patients, including those with mucinous carcinoma peritonei (MCP) who wish to preserve fertility.[30]

Pathology & Molecular Classification

Appendiceal neoplasms are a heterogenous group of tumors with controversial historic and confusing nomenclature. Unified terminology is key in obtaining correct classification and subsequent clinical management for appendiceal tumors with and without peritoneal involvement. The following pathologic classifications are based on the 9th edition of the AJCC and 5th edition of the *WHO Classification of Digestive System Tumors*.[11-13,31-34]

Appendiceal Serrated Lesions and Polyps

Serrated epithelial lesions arising in the appendix can be reactive or neoplastic. The histologic diagnosis of reactive mucosal hyperplasia refers to flat, serrated surface epithelium lacking cytologic features of dysplasia often arising in the post-inflammatory repair setting after acute appendicitis, appendiceal diverticular disease, or after an interval appendectomy.[32] Nomenclature for appendiceal serrated lesions and polyps is emerging and varies in the literature. The WHO 5th edition classifies serrated entities as mucosal hyperplasia, hyperplastic polyp,

Version 2.2026 © 2026 National Comprehensive Cancer Network© (NCCN©), All rights reserved. NCCN Guidelines® and this illustration may not be reproduced in any form without the express written permission of NCCN.

PLEASE NOTE that use of this NCCN Content is governed by the End-User License Agreement, and you MAY NOT distribute this Content or use it with any artificial intelligence model or tool.
Printed by Máximo López Chenlo on 5/4/2026 6:12:29 PM. Copyright © 2026 National Comprehensive Cancer Network, Inc. All Rights Reserved.

serrated lesion with dysplasia, and serrated lesion without dysplasia. Non-serrated dysplastic lesions, similar to their colorectal counterparts, can also arise within the appendix. However, the clinical significance of the categories is the same in that dysplastic lesions have a risk of progression to invasive adenocarcinoma and non-dysplastic lesions do not. Dysplastic serrated lesions in the appendix may be distinct from colorectal counterparts in the absence of *BRAF* mutations and presence of *KRAS* and *GNAS* mutations.[32,35-37]

Appendiceal Mucinous Neoplasms

Current preferred terminology for appendiceal mucinous neoplasms is low-grade appendiceal mucinous neoplasm (LAMN) and high-grade appendiceal mucinous neoplasm (HAMN).[32,34] Historic terminology no longer recommended includes: mucinous tumor of uncertain malignant potential, borderline tumor of the appendix, and mucinous cystadenocarcinoma of the appendix.

By definition, LAMN and HAMN refer to appendiceal mucinous neoplasms that do not demonstrate an infiltrative growth pattern or desmoplasia. Instead both are characterized by dysplastic mucinous epithelium, accompanied by effacement of the lamina propria, loss of lymphoid tissue, and presence of submucosal fibrosis. Characteristic cytologic and architectural features separate these two entities. LAMN demonstrates tall mucinous epithelial cells with mild cytologic atypia in a villous or flat arrangement. HAMN retains similar features as LAMN but shows progression to a more aggressive neoplasm with the acquisition of unequivocal high-grade cytologic features and more complex architecture. Both LAMN and HAMN exhibit a rounded, pushing pattern of invasion and do not demonstrate an infiltrative growth pattern or associated desmoplastic response that defines invasive adenocarcinoma. Mucin pools, acellular or with dysplastic mucinous epithelium, are common in both neoplasms and may extend into the serosa and beyond. LAMN confined to the submucosa or muscularis propria, including acellular or mucinous epithelium, is staged as carcinoma in situ (pTis). pT1 and pT2 are not applicable. A tumor that extends into subserosa is staged as pT3. pT4 refers to a tumor that perforates the appendix with extension of either acellular mucin or mucin with neoplastic cells. pT4 is further subdivided into invasion into the visceral peritoneum involving serosa of the appendix or mesoappendix (pT4a) and direct invasion or adherence to adjacent organs or structures that is not luminal or mural extension (T4b). HAMN is staged as mucinous adenocarcinoma based on recent evidence of biologic potential. However, robust data are rare and limited.[11-13,34,35,38-40] Mucin that involves peritoneal surfaces beyond the appendix are staged as pM1a if the mucin is acellular and pM1b if the mucin contains neoplastic epithelial cells.

Molecular studies performed on LAMN/HAMNs are limited and also fraught with challenges extending from confusing historical nomenclature. However, recent analyses incorporating expert GI pathology review have been published. Findings on small- and large-scale next-generation sequencing (NGS) panels show the vast majority of LAMNs and HAMNs harbor *KRAS* and *GNAS* mutations.[41-43] Activating *BRAF* mutations are rarely seen and when discovered are often class II and not *BRAF* V600E. *TP53* mutations were not identified in LAMNs in these careful studies, but were identified in a percentage of HAMNs as well as mucinous adenocarcinomas.[43-46] Neither mismatch repair deficiency (dMMR) nor microsatellite instability (MSI) have been identified in LAMNs or HAMNs, outside of patients with suspicion of Lynch syndrome, reviewed by expert GI pathologists.[47]

Peritoneal metastases from LAMN or HAMN may have a discordant, more aggressive disease histology and should be treated accordingly.

Version 2.2026 © 2026 National Comprehensive Cancer Network© (NCCN©), All rights reserved. NCCN Guidelines® and this illustration may not be reproduced in any form without the express written permission of NCCN.

PLEASE NOTE that use of this NCCN Content is governed by the End-User License Agreement, and you MAY NOT distribute this Content or use it with any artificial intelligence model or tool.
Printed by Máximo López Chenlo on 5/4/2026 6:12:29 PM. Copyright © 2026 National Comprehensive Cancer Network, Inc. All Rights Reserved.

Appendiceal Adenocarcinoma (AA)

Outside of appendiceal mucinous neoplasms (LAMN, HAMN), primary ACs are rare. AA demonstrate a variety of histologic patterns similar to those arising in the colorectum. They can be generally divided into mucinous and non-mucinous adenocarcinomas. Mucinous AAs can be challenging to distinguish from mucinous neoplasms (LAMN and HAMN). However, AA is highly cellular, has high-grade nuclear features, and must show an infiltrative growth pattern with a desmoplastic response.[32,34,48,49] Mucinous adenocarcinoma comprise >50% extracellular mucin, with floating strips, glands, or clusters of neoplastic mucinous epithelial cells. Signet ring cell adenocarcinoma refers to a tumor with >50% consisting of signet ring cells, similar to signet ring cell carcinoma arising elsewhere within the GI tract. UC is an aggressive subtype of carcinoma characterized by lack of morphologic, immunohistochemical, and molecular evidence of differentiation beyond that of epithelial origin.

AJCC grading of mucinous adenocarcinomas and non-mucinous adenocarcinomas involves a similar three-tier grading scheme. However, cytologic and architectural criteria are different. For mucinous adenocarcinoma, grade 1 (well-differentiated) tumors demonstrate low-grade cytologic atypia and lack signet ring cells. Grade 2 (moderately differentiated) tumors show a mix of low-grade and high-grade cytologic atypia but lack a signet ring cell component. Grade 3 (poorly differentiated) tumors exhibit high-grade cytologic atypia and the presence of a signet ring cell component, usually >10%. Non mucinous adenocarcinomas are graded similar to other locations in the colorectum: G1 (well differentiated, >95% gland formation), G2 (moderately differentiated, 50%–95% gland formation), and G3 (poorly differentiated, <50% gland formation).

Staging is similar for both mucinous adenocarcinoma and non-mucinous adenocarcinoma: pT1 invasion into the submucosa; pT2 into the muscularis propria; pT3 through the muscularis propria and into the subserosa or mesoappendix; pT4a through the visceral peritoneum, including acellular mucin or mucinous epithelium involving serosa; and T4b direct invasion or adherence to adjacent organs or structures. Lymph node (pN) categories are also similar: pN1a tumor involvement in one regional lymph node; pN1b tumor involvement in two or three positive regional lymph nodes; pN1c with no tumor involvement in lymph nodes but tumor deposits are identified in the subserosa or mesentery; and pN2 tumor involving ≥4 regional lymph nodes.

AA rarely demonstrates dMMR or MSI-high (MSI-H), unlike adenocarcinomas of the colorectum.[50] Several studies have sought to develop a molecular profile of appendiceal neoplasms to guide clinical decision-making and identify similarities and differences from colon cancer. However, early studies grouped LAMN/HAMN in with other appendiceal neoplasms creating a challenge in interpreting prognostic significance.[51,52] A recent molecular study sequenced AA from 273 patients following a consensus diagnosis provided by expert GI pathologists. The tumors included were mucinous AA, goblet cell adenocarcinoma (GCA), and colonic-type (non-mucinous) adenocarcinoma. All tumors were MMR proficient (pMMR). In addition, within the mucinous adenocarcinoma group, the authors identified four distinct molecular subtypes: a clinically indolent *RAS*-mutant predominant subtype (*RAS*-mutant/*GNAS*-wild-type/all *TP53*-wild-type); a chemotherapy-resistant *GNAS*-mutant predominant subtype (*GNAS*-mutant/*RAS*-wild-type or *GNAS*-mutant/*RAS*-mutant, and all *TP53*-wild-type); an aggressive, highly aneuploid *TP53*-mutant predominant subtype (all *TP53* mutant); and a triple-negative subtype (*RAS*/*GNAS*/*TP53*-wild-type).[53] These molecular subtypes and associated clinical outcomes were similar in both the colonic type, non-mucinous adenocarcinoma and GCA groups, providing support for incorporating molecular signatures into the clinical management of AA.[53]

Version 2.2026 © 2026 National Comprehensive Cancer Network© (NCCN©), All rights reserved. NCCN Guidelines® and this illustration may not be reproduced in any form without the express written permission of NCCN.

PLEASE NOTE that use of this NCCN Content is governed by the End-User License Agreement, and you MAY NOT distribute this Content or use it with any artificial intelligence model or tool.
Printed by Máximo López Chenlo on 5/4/2026 6:12:29 PM. Copyright © 2026 National Comprehensive Cancer Network, Inc. All Rights Reserved.

A study of 266 patients with metastatic AA revealed similar frequently mutated genes in the following descending order: *RAS* (*KRAS* or *NRAS*), *GNAS*, *TP53*, *SMAD4*, *PIK3CA* and *APC*. Well- and moderately differentiated AA were enriched for *RAS* and *GNAS* compared to poorly differentiated tumors and had a lower rate of *TP53* mutations. In addition, this study evaluated the concordance between circulating tumor DNA (ctDNA) and tissue-based mutational profiling. Compared to colorectal cancer (CRC), AA was less likely to shed ctDNA with only 38% of patients found to have detectable ctDNA.[54] Of the tumors with detectable ctDNA, *TP53* and *KRAS* were the most commonly mutated genes, similar to tissue-based studies on higher-grade AA. Separate studies have reported similar discordant results between tissue-based and ctDNA assays highlighting the challenges of utilizing ctDNA to inform prognosis and therapy.[55]

Goblet Cell Adenocarcinoma

Appendiceal GCAs were previously classified as NETs but are now recognized as a distinct clinicopathologic entity with biologic potential similar to adenocarcinomas.[32] Historic terminology no longer recommended includes goblet cell carcinoid, goblet cell type adenocarcinoid, mucinous carcinoid, and crypt cell carcinoma.[35]

By definition, GCAs must demonstrate at least some component of characteristic low-grade morphologic features, which include tubules of goblet-like cells and occasional evidence of endocrine or Paneth cell differentiation. Nuclear cytologic atypia is mild. The tumor cells may be arranged in groups of cells without lumina or as fused tubules. Extracellular mucin is often identified and can sometimes be abundant. High-grade morphology is defined by high-grade nuclear cytologic atypia, signet ring cell morphology, and abundant mitotic activity. Necrosis may be present. Tumor cells invade as single cells, in sheets, or demonstrate complex anastomosing tubules. Perineural invasion is commonly seen in both low-grade and high-grade GCA. However, lymphovascular invasion is more commonly associated with high-grade morphology. GCAs are graded according to a unique system: Grade 1: >75% low-grade growth pattern; Grade 2: 50% to 75% low-grade growth pattern; and Grade 3: >50% high-grade growth pattern.[32] If >50% of the neoplastic cell population is comprised of signet ring cell morphology, and a low-grade component is not identified, the tumor is categorized as a signet ring cell adenocarcinoma. GCAs are staged the same as other AA.[32,33]

Similar to other appendiceal neoplasms, GCA are predominately pMMR.[56] Sequencing studies show GCA are biologically distinct from colorectal adenocarcinoma in the lack of *APC*, *KRAS*, and *TP53* mutations.[56,57] Instead, GCA more often harbor alterations in chromatin remodeling complex pathway genes including *ARID1A*, *ARID2*, *KDM6A*, and *KMT2D* (*MLL2*)] or WNT signaling-associated genes *USP9X*, *NOTCH1*, *CTNNA1*, *CTNNB1*, and *TRRAP*.[57,58]

Mucinous Carcinoma Peritonei (Pseudomyxoma Peritonei)

Pseudomyxoma peritonei (PMP) is a term used to describe the clinical presentation of mucinous tumor deposits in the peritoneum also described as diffuse progressive mucinous ascites.[13,59] The WHO uses PMP to describe all peritoneal mucinous tumors regardless of grade.[32] The current histologic terminology for mucinous neoplasms in the peritoneum is MCP.[11-13,32,33] Historic terminology no longer recommended includes: disseminated peritoneal adenomucinosis and peritoneal mucinous carcinomatosis with or without signet ring cells.

It is now understood that PMP is most often secondary to LAMN and HAMN.[13] Nomenclature, as well as pathologic grade and stage, for entities within the peritoneum has evolved in an attempt to mirror biologic potential of mucinous neoplasms within the appendix.[11-13,32,33,60] Accordingly, appendiceal neoplasms with intraperitoneal acellular mucin are staged as

Version 2.2026 © 2026 National Comprehensive Cancer Network© (NCCN©), All rights reserved. NCCN Guidelines® and this illustration may not be reproduced in any form without the express written permission of NCCN.

PLEASE NOTE that use of this NCCN Content is governed by the End-User License Agreement, and you MAY NOT distribute this Content or use it with any artificial intelligence model or tool.
Printed by Máximo López Chenlo on 5/4/2026 6:12:29 PM. Copyright © 2026 National Comprehensive Cancer Network, Inc. All Rights Reserved.

pM1a, mucinous deposits containing tumor cells as pM1b, and metastasis to sites other than the peritoneum as pM1c. The AJCC provides a grading scheme for the neoplastic cells within peritoneal mucin. Grade 1 MCP/PMP (well-differentiated) is defined as harboring low-grade cytologic atypia and absence of signet ring cells. Grade 2 MCP/PMP (moderately differentiated) shows a mix of low-grade and high-grade cytologic atypia and absence of signet ring cells. Grade 3 MCP/PMP (poorly differentiated) refers to neoplastic cells with high-grade cytologic atypia usually with a signet ring cell component.[11-13,32,33,60] For patients with previous treatment, a peritoneal regression grading score has been proposed although only validated in combination with peritoneal cytology.[13,61,62]

Recent studies with careful histologic review focused on molecular alterations in peritoneal disease only (PMP).[43] In one study, alterations in *TP53, SMAD4, ATM, CDKN2A,* and mTOR pathway genes were associated with older mean age, higher AJCC/WHO histologic grade, lymphovascular invasion, perineural invasion, regional lymph node metastasis, lower mean PCI, and lower OS rates. Several other genomic studies focused on cellular peritoneal mucin demonstrated a higher percentage of *TP53* mutations along with alterations in *SMAD4* and *ARID1A*.[39,46] Independently, *TP53* mutations have been associated with a worse prognosis in these patients.[63]

Appendiceal Neuroendocrine Neoplasms

See the NCCN Guidelines for Neuroendocrine and Adrenal Tumors (available at www.NCCN.org) for more information.

Targeted Therapy and Appendiceal Neoplasms

Molecular alterations with associated targeted therapy options have been reported in a subset of patients with AA, such as *KRAS* G12C, *PIK3CA*, and *NTRK1* fusions. However, several large genomic studies have shown AA is molecularly distinct from colorectal adenocarcinoma.[53-55,64] For example, *BRAF* V600E is rarely observed and the incidence of MSI-H or dMMR in all subtypes of primary and disseminated appendiceal neoplasm is very low.[55,65] Recent large genomic studies have reported tumor mutational burden (TMB) and MSI status in patients with AA. In one study of all stage AA, AA had a low TMB compared to rectal and colon cancers and only 1.3% of AA were MSI-H.[65,66] See *Palliative Systemic Therapy for Advanced or Metastatic Disease*, below, for more information on targeted therapy options for AA.

Imaging

Computed Tomography (CT) Scan

CT is the imagining modality of choice due to its high diagnostic accuracy, helping to differentiate between appendicitis and appendiceal neoplasms as well as extent of disease in cases of malignancy.[67,68] CT imaging of acute appendicitis shows appendiceal thickening defined as the outer diameter measuring >6 mm and inflammatory thickening of the appendiceal wall measuring ≥3 mm, in addition to mural hyperenhancement.[69] Similarly, NETs of the appendix appear on CT with the characteristics of appendicitis but with the addition of a small mass located toward the tip of the appendix. These findings mimic the characteristics of appendicoliths, making NET hard to definitively diagnosis before pathology review. Non-mucinous neoplasm of the appendix will also resemble appendicitis but with the presence of a soft tissue mass either obstructing the appendiceal lumen or infiltrating the appendiceal wall. Other imaging findings may include direct infiltration to surrounding organs, lymphadenopathy, and possible metastasis.[69] CT images of mucinous neoplasms are not usually consistent with appendicitis unless infection and inflammation arise. These findings are due in part to the large quantities of mucin being secreted into the lumen causing luminal distention without significant inflammation.[20,69] Other clinical manifestations of mucinous neoplasms may include a palpable

Version 2.2026 © 2026 National Comprehensive Cancer Network© (NCCN©), All rights reserved. NCCN Guidelines® and this illustration may not be reproduced in any form without the express written permission of NCCN.

PLEASE NOTE that use of this NCCN Content is governed by the End-User License Agreement, and you MAY NOT distribute this Content or use it with any artificial intelligence model or tool.
Printed by Máximo López Chenlo on 5/4/2026 6:12:29 PM. Copyright © 2026 National Comprehensive Cancer Network, Inc. All Rights Reserved.

mass; PMP causing an increase in abdominal girth; torsion and right ureteral obstruction; and intussusception.[69]

FDG-PET/CT

PET using ^{18}fluorodeoxyglucose (FDG) is not indicated in the workup for appendiceal neoplasms or cancers, mainly due to low sensitivities in both low-grade and high-grade lesions, with or without concomitant CT. In one study, the lower sensitivity for detecting high-grade and low-grade lesions with PET alone compared to PET/CT was not statistically significant.[70] Importantly, CT was the factor that improved imaging of these cases, and the authors concluded that FDG-PET should not be used for patients with appendiceal lesions. Patients with confirmed or suspected appendiceal neoplasms may be advised to undergo FDG-PET scans to aid in the detection of potential metastases in the liver, and to help establish the peritoneal cancer index (PCI), a tool used for staging the extent of peritoneal seeding.[28,71,72]

Imaging for patients with neuroendocrine neoplasms may include contrast-enhanced CT of the chest/abdomen/pelvis and view of the liver, the most frequent metastatic site. Somatostatin receptor imaging with ^{68}Ga-DOTATATE PET/CT should not be used routinely for diagnostic workup since contrast-enhanced CT is highly sensitive, but may be considered for neuroendocrine neoplasms, as discussed in the NCCN Guidelines for Neuroendocrine and Adrenal Tumors (available at www.NCCN.org).

MRI

MRI can be considered as an imaging option if CT findings in the setting of recurrent disease are normal, but disease presence is suspected. CT may not be feasible in several settings, warranting MRI of the abdomen to determine the extent of extraperitoneal disease.[71,73] Preoperative use of MRI has demonstrated value for staging of HAMN and LAMN, regardless of CT accessibility.[70,74]

Diagnostic Laparoscopy

Following initial recommended imaging, diagnostic laparoscopy is an option to allow surgeons to obtain further information about the organs and adjacent regions that may be affected by lesions. If no metastases or peritoneal disease are found by imaging analyses, laparoscopy is indicated to be performed by a trained surgical oncologist. Diagnostic laparoscopy may help estimate the likelihood of complete cytoreduction as well as obtain tissue samples.[75] Furthermore, since nodal disease has been shown to predict recurrence in patients with nonmetastatic AA, workup including diagnostic laparoscopy can be helpful for prognostication by identifying positive lymph nodes.[76] A study of 685 patients who underwent surgery for appendiceal neoplasms revealed that 11% of the individuals underwent diagnostic laparoscopy before surgery.[77] Diagnostic laparoscopy was utilized to assess disease burden and further support the findings from imaging and staging of patients with high-risk histology, which they conclude could help avoid unnecessary laparotomy in many cases.

Image-Guided Biopsy

As part of diagnostic workup, image-guided biopsy may be considered as an alternative to diagnostic laparoscopy in select situations. Image-guided biopsy is preferred for AC with possible extraperitoneal disease with significant ascites or for peritoneal-only disease where a non-surgical approach is preferred and lesions may be safely accessible percutaneously. If lesions are inaccessible, surgical biopsy may be needed for diagnostic confirmation.

While FDG-PET/CT is regarded as one of the more advantageous options for biopsy since it can clearly identify hypermetabolic regions of target tissues, it is seldom performed since the lack of real-time imaging during sampling limits the denotation of the FDG-active area.[78] Similarly,

Version 2.2026 © 2026 National Comprehensive Cancer Network© (NCCN©), All rights reserved. NCCN Guidelines® and this illustration may not be reproduced in any form without the express written permission of NCCN.

PLEASE NOTE that use of this NCCN Content is governed by the End-User License Agreement, and you MAY NOT distribute this Content or use it with any artificial intelligence model or tool.
Printed by Máximo López Chenlo on 5/4/2026 6:12:29 PM. Copyright © 2026 National Comprehensive Cancer Network, Inc. All Rights Reserved.

PET/CT is less useful in cases where malignant cells exhibit hypometabolic activity, leading to evasion of detection.[79]

Surgical Resection

Surgical resection for appendiceal neoplasms and cancers is done to prevent progression and recurrence of localized disease or to remove peritoneal deposits for metastatic disease. For lower-risk localized disease, appendectomy is routinely performed to remove tumor and alleviate inflammation of the lower GI tract and potential rupture, which could lead to peritoneal spread, peritonitis, and/or other inflammatory processes. Higher-risk histologies may require right hemicolectomy (RHC) for resection of localized disease. For metastatic disease to the peritoneum, cytoreductive surgery (CRS), with or without intraperitoneal chemotherapy (IPCT), is generally the preferred surgical option if complete resection of peritoneal disease is possible. Effective surgical options are available on a case-by-case basis, and specific techniques are discussed in more detail in the following sections. This is also discussed in greater detail, including assessment of the PCI score, in the later section on CRS/IPCT.

Appendectomy

Appendectomy is a well-refined surgical procedure that is commonly performed to treat appendicitis. An appendectomy involves the removal of the whole vermiform appendix by either open or laparoscopic surgery. These methods have utility in cancer care since removing an appendix with a localized appendiceal neoplasm has a strong chance of curing the disease.[80] Moreover, appendiceal lesions are known to present as appendicitis since the symptoms patients experience from either condition can be similar. Studies have reported that appendiceal neoplasms can be found during (visually) and after (upon pathologic examination) an appendectomy for appendicitis or other GI tests.[81,82] A retrospective study of patients who underwent appendectomies found that 2.1% of all patients had neoplasms, with the majority being NETs.[83] A different retrospective review revealed 0.4% patients who underwent appendectomies had carcinoid appendiceal tumors.[84] In both of these studies, the patients received surgery for appendicitis. Further, 9 patients of 3071 with appendicitis were found to have appendiceal lesions, of which two cases were low-grade mucinous tumors.[81] These nine patients were successfully treated with methods including laparoscopic appendectomy and partial cecectomy. Appendectomy successfully treated HAMN and LAMN, but additional examinations may be required to be certain an invasive adenocarcinoma is not present.[75]

The incidence of appendiceal neoplasms may be markedly higher with complicated appendicitis. A review of 387 patients with complicated appendicitis reported that 16.1% were found to have appendiceal neoplasms or cancers following surgery.[85] The most common tumor type was mucinous neoplasm (54%), although NET (19%) and AA (13%) were also observed. These findings underscore the risks of non-operative or medical management of complicated appendicitis and suggest that radiologic and clinical predictors should be considered to guide treatment.

A study of 138 patients across 14 medical centers at a follow-up of 13 years compared the impact of different resection modalities.[86] Of the 138 patients with appendiceal mucinous neoplasms, 70 had appendectomies, 26 had cecectomies, and 37 had RHC. They found that patients who underwent RHC or appendectomy had similar OS and disease-specific survival (DSS) at 5 years post-surgery. The more extensive surgical techniques (eg, cecectomy, RHC) offered no advantage in these metrics for those patients with localized low-grade neoplasms.

Laparoscopic appendectomy has become widely popular for patients with appendicitis, or cancer presenting as appendicitis. Compared to open appendectomy, this method is associated with decreases in infection rates, recovery times, lengths of hospital stay, and mortality

Version 2.2026 © 2026 National Comprehensive Cancer Network© (NCCN©), All rights reserved. NCCN Guidelines® and this illustration may not be reproduced in any form without the express written permission of NCCN.

PLEASE NOTE that use of this NCCN Content is governed by the End-User License Agreement, and you MAY NOT distribute this Content or use it with any artificial intelligence model or tool.
Printed by Máximo López Chenlo on 5/4/2026 6:12:29 PM. Copyright © 2026 National Comprehensive Cancer Network, Inc. All Rights Reserved.

rates.[81,87,88] Open appendectomy can be considered in cases where laparoscopy is not feasible, the patient is hemodynamically unstable, or when equipment or expertise is absent in a clinical setting.[89,90]

Cecal Cuff Resection

Surgical intervention of appendiceal tumors that reside in the appendiceal orifice, the part of the appendix that opens into the cecum, presents a challenge for surgeons since the location requires careful consideration of surrounding structures while maintaining healthy margins. A cecal cuff resection involves surgical removal of the whole appendix along with a small portion of the cecum, without compromising the ileocecal valve.[91] A case report of a patient with a sessile serrated lesion discovered during colonoscopy found that the combination of a standard laparoscopic appendectomy and cecal cuff resection led to a successful patient outcome while preserving most of the healthy cecal tissue.[92] A cecal cuff resection may be considered for LAMN/HAMN that was resected via appendectomy with positive margins. If achieving a negative-margin resection with complete cytoreduction would result in narrowing of the ileocecal valve, ileocecectomy (as opposed to RHC) is the preferred option to minimize exposure of the retroperitoneum and the extent of colonic resection, given that lymph node harvest is not required.

Right Hemicolectomy (RHC)

Patients with higher-risk appendiceal cancers, such as with AA, GCA, or NET often require RHC, a procedure involving the removal of the right side of the colon and the entire appendix, rather than an appendectomy.[75,93,94]

RHC and appendectomy have been historically compared for their effectiveness in decreasing progressive disease and increasing OS. A small study of 36 patients with AA helped solidify the notion that curative resection survival rates vary widely based on the histologic type, T stage, and tumor grade (differentiation status).[95] Some reports conclude that RHC improved 1-, 3-, and 5-year survival rates in patients with appendiceal neoplasms when compared to appendectomy, especially for poorly or moderately differentiated stage 2 lesions.[96,97] Another multicenter retrospective analysis of 168 patients with T1 AA compared the OS rates after undergoing either appendectomy or RHC.[98] The 1-, 3-, and 5-year postoperative OS rates were 87.4%, 84.8%, and 71.8% for the appendectomy group and 95.2%, 91.4%, and 82.8% for the RHC group, yielding no significant differences between the two surgical modalities. A report comparing the histology and size of appendiceal tumors and lymph node involvement found that in patients with well-differentiated NETs, who may have a higher rate of nodal metastases in larger tumors (11–20 mm), favorable outcomes are not further improved by RHC.[99]

A study involving 501 patients diagnosed with epithelial appendiceal lesions with peritoneal seeding found no survival advantage in patients treated with RHC when compared to appendectomy.[100] The study concluded that RHC can be avoided in mucinous appendiceal tumors with peritoneal seeding unless there is substantial metastatic involvement documented by biopsy or an inadequate resection margin. Again, these studies can be hard to interpret given the mixture of low- and high-risk disease.

Based on these results, the NCCN Panel recommends that appendectomy alone is sufficient for LAMN/HAMN localized to the appendix and completely resected with negative margins. In cases where there are concerns regarding margin status, cecal cuff resection with or without ileocecectomy may also be sufficient, depending on the extent of involvement. In rare cases, right hemicolectomy (RHC) may be required to achieve negative margin resection. However, the management of HAMN remains somewhat controversial, with some

Version 2.2026 © 2026 National Comprehensive Cancer Network© (NCCN©), All rights reserved. NCCN Guidelines® and this illustration may not be reproduced in any form without the express written permission of NCCN.

PLEASE NOTE that use of this NCCN Content is governed by the End-User License Agreement, and you MAY NOT distribute this Content or use it with any artificial intelligence model or tool.
Printed by Máximo López Chenlo on 5/4/2026 6:12:29 PM. Copyright © 2026 National Comprehensive Cancer Network, Inc. All Rights Reserved.

advocating for RHC. RHC is recommended for localized AA, GCA, or UC-not otherwise specified (NOS) histologies due to their higher risk of progression and recurrence. Adjuvant therapy should be strongly considered following RHC when nodal disease or perforation was noted during surgery or with high-risk features, as discussed in *Systemic Therapy for Resectable Disease* below.

Lymph Node Dissection

Lymph node removal during surgery for AC is common when the lesion has metastasized to regional lymph nodes, often warranting RHC even if the disease is confined to the appendix. Since resection of lymph nodes can allow for more precise staging, the prospect of curative outcomes may be greater.[75] Lymph node dissection, defined as at least 12 lymph nodes removed and examined (extrapolated from NCCN Guidelines for Colon Cancer) is crucial for accurate staging, per the AJCC and College of American Pathologists.[34,101] A major determinant of the necessity of lymph node dissection for AC is the histology of the tumor. Regionally advanced well-differentiated appendiceal tumors tend to have similar lymph node positivity compared to mixed-histology tumors, but the treatment of the two tumor histologies is often different. Generally, well-differentiated tumors have lower rates of metastasis than those of mixed-histology, but lymph node removal and more extensive surgery may benefit treatment of mixed-histology tumors.[94]

The need for a post-appendectomy RHC is highly dependent upon the extent of lymph node involvement for progressive disease. In 1731 patients who had either well-differentiated or mixed-histology tumors, the type of surgery alone did not affect OS. However, tumor size was predictive of lymph node involvement, where higher rates of nodal metastases were seen in tumors between 11 to 20 mm for mixed-histology than those ≤10 mm.[99] Although lymph node involvement was similar between the two histologies, patients with well-differentiated tumors were able to undergo an appendectomy alone or an RHC alone, with no difference in long-term OS.

There is controversy regarding the optimal number of lymph nodes to resect and evaluate for patients with AC. A mixed cohort of 1046 patients with mucinous or non-mucinous appendiceal tumors revealed a relationship between lymph nodes resected and node positivity for OS.[102] The finding that the rate of node-positive cancer increased with the number of regional nodes resected (up to 10 total nodes), was noted, but beyond 10 nodes resected the rate plateaued. Importantly, removing ≥12 nodes, as per the NCCN Guidelines for Colon Cancer, was associated with greater rates of OS when compared to removing <12, though there is no consensus for AA. This concept was investigated by Winicki et al where the number of lymph nodes harvested was evaluated for the potential impact on patient survival in mucinous and non-mucinous AA.[103] Although the survival benefit was maximized when harvesting ≥15 nodes for mucinous and 12 nodes for non-mucinous lesions, the main predictors of OS were the quality of lymph node removal surgery rather than surgery type (eg, appendectomy, RHC) and histology.

Treatment of Peritoneal Metastasis

Peritoneal carcinomatosis (PC) is a neoplasm whose origin is from a primary tumor tissue (eg, appendix) that settles in the peritoneal space within the abdominal cavity. This spread can present a challenge for clinicians since it may be visually difficult to detect among surrounding structures and treatment can be limited owing to drug penetration and distribution issues. Therefore, the preferred treatment for appendiceal neoplasms and cancers with peritoneal spread is CRS, with or without IPCT, provided that a complete CRS is possible and the approach is recommended upon multidisciplinary discussion.

Version 2.2026 © 2026 National Comprehensive Cancer Network© (NCCN©), All rights reserved. NCCN Guidelines® and this illustration may not be reproduced in any form without the express written permission of NCCN.

PLEASE NOTE that use of this NCCN Content is governed by the End-User License Agreement, and you MAY NOT distribute this Content or use it with any artificial intelligence model or tool.
Printed by Máximo López Chenlo on 5/4/2026 6:12:29 PM. Copyright © 2026 National Comprehensive Cancer Network, Inc. All Rights Reserved.

CRS/IPCT is recommended for eligible patients with either low- or high-grade peritoneal deposits, although the specific considerations differ. For low-grade deposits or in cases where the pathology of the peritoneal deposits is unknown, observation may be considered in cases where CRS is not possible or mucin is acellular and localized to the periappendix area. A prospective study of 41 patients concluded that resected LAMN, including some with limited peritoneal spread, had a low (4.9%) risk of recurrence after appendectomy and local clearance of mucin.[104] Another study of 125 patients with LAMN similarly concluded that overall recurrence risk for LAMN is low and appendectomy is sufficient for most cases, although those with acellular mucin confined to the right lower quadrant and a tumor size of <2 cm are at higher risk of recurrence.[105] Contingent to an observation plan, LAMN histology must be confirmed by expert pathologic review.

For AA, GCA, or UC-NOS primaries or LAMN/HAMN with high-grade peritoneal metastases, neoadjuvant systemic therapy is recommended for up to 6 months before surgery. However, the data on whether neoadjuvant therapy improves outcomes in appendix cancer is mixed, as described below in *Systemic Therapy for Resectable Disease*.

Cytoreductive Surgery (CRS)/Intraperitoneal Chemotherapy (IPCT)

CRS with concomitant IPCT is a treatment option consisting of a surgical procedure to remove all detectable signs of cancer from the abdominal space followed by chemotherapy applied directly to the peritoneum. CRS and IPCT have been used with reasonable success in patients who have PC stemming from primary AC. Compared to CRS alone, CRS + IPCT can extend patient OS and median PFS, especially for those where CRS was inadequate.[106] For peritoneal metastases from AC, CRS and IPCT give select patients an increased chance of survival compared to systemic therapies.

Systemic therapies have particularly poor absorption in the peritoneum, explained by meager responses to intravenous chemotherapies delivered to treat PC before or after a CRS.[107] Utilizing heat to increase drug penetration and effectiveness in the abdominal cavity, called hyperthermic intraperitoneal chemotherapy (HIPEC), is a commonly employed type of IPCT that has improved outcomes in patients with PC of various tissue origins.[108,109] However, specific techniques used for IPCT can differ between institutions, and therefore, the NCCN Panel does not recommend specific IPCT procedures or techniques.

A retrospective database report of 18,055 patients with AC compared the OS of patients receiving CRS + HIPEC versus surgery only and found that patients receiving CRS + HIPEC had a 5-year OS of 66%, compared to the 62% of those receiving surgery alone ($P < .01$), and a higher 5-year OS for patients with well-differentiated cancers (eg, AA) when compared to all other treatment modalities (surgery + neoadjuvant/adjuvant chemotherapy, chemotherapy only, and neither surgery nor chemotherapy).[110] Importantly, patients who received chemotherapy only had the poorest 5-year OS among all treatment groups, though this finding may have bias against those not deemed a candidate for surgery within this retrospective series.

Low-grade and well-differentiated AA histologies tend to be more amenable to this treatment combination, often leading to better patient outcomes and improved OS.[106,111-113] The presence of acellular mucin in the abdomen, when mucinous content is localized to the periappendix area, is associated with better patient outcomes than neoplasms with cellular mucin since there are no malignant cells directly in the mucinous deposits.[114] Accordingly, CRS and IPCT can be performed in patients with acellular mucinous appendiceal neoplasms with a reasonable potential of achieving a longer OS and DFS when compared to if those patients had cellular mucinous neoplasms. A study evaluating long-term

Version 2.2026 © 2026 National Comprehensive Cancer Network© (NCCN©), All rights reserved. NCCN Guidelines® and this illustration may not be reproduced in any form without the express written permission of NCCN.

PLEASE NOTE that use of this NCCN Content is governed by the End-User License Agreement, and you MAY NOT distribute this Content or use it with any artificial intelligence model or tool.
Printed by Máximo López Chenlo on 5/4/2026 6:12:29 PM. Copyright © 2026 National Comprehensive Cancer Network, Inc. All Rights Reserved.

outcomes of patients with appendiceal neoplasms and acellular mucin (classified as M1a disease) compared to patients with mucin-containing tumor cells (classified as M1b disease) found that there are significantly different outcomes after CRS + HIPEC.[115] At an overall median follow-up of 7.6 years, patients with M1a disease experienced no recurrences or metastases while 67% of patients with M1b disease experienced recurrence, with 33% of these patients dying during the study period. Patients with primary LAMNs or HAMNs who experience peritoneal disease should be assessed for mucinous deposits since potential procedural protocols are influenced by factors such as time of treatment, severity of disease, and the need for extensive care afterward.

Some studies have also investigated the role of CRS in high-grade AC. A study of 46 patients with mucinous and non-mucinous neoplasms originating from AC resulting in PC underwent CRS to improve disease management.[116] Median DFS and OS after CRS were 20.5 months and 56.4 months, respectively, with a 5-year OS of 45%. Variables involved in survival data in most studies for these methods include age, extent of CRS, previous chemotherapy, CA 19-9 levels, and tumor grade.[116,117] A similar study looked at the outcome of 282 patients with PC originating from AA, with complete CRS achieved in 82% of patients involved.[118] Median OS in this study was 6.72 years with a 5-year OS probability of 52.7%.

Laparoscopic CRS/IPCT, a less invasive version of CRS/IPCT, has been studied for its safety and effectiveness in patients with different appendiceal-derived histologies with some promising results.[119,120] Though this type of CRS/IPCT is not yet widely used, there is potential for decreasing morbidities that usually affect patients who undergo the standard CRS/IPCT procedures.

Laparoscopic Determination of CRS/IPCT Candidacy

PC originating from appendiceal neoplasms often warrants diagnostic laparoscopy or CT in order to help determine if a complete CRS/IPCT could potentially eradicate peritoneal disease. Laparoscopy is used before and during CRS to aid in staging and determination of candidacy and to limit the invasiveness of the procedure. Diagnostic laparoscopy may also be considered to help exclude patients from CRS/IPCT candidacy due to high-volume disease and/or unresectability.[121] Common findings that may exclude a patient from CRS/IPCT candidacy are extensive small bowel serosal involvement and/or high PCI values.

A single-center, retrospective study of 141 patients who underwent laparoscopies to determine whether patients were potential candidates for CRS/HIPEC found that of the 67 patients whose primary malignancy site was appendix, 48 of these patients who were deemed candidates underwent CRS/HIPEC.[122] The study found an 82.8% positive predictive value for diagnostic laparoscopy, and concluded that the technique was safe, effective, and accurate for determining patient candidacy for CRS and HIPEC.

Peritoneal Cancer Index (PCI) and Completeness of Cytoreduction (CC)

The PCI, an assessment of extent of metastatic disease that aids in estimating the probability of complete cytoreduction, is generally determined preoperatively upon diagnostic imaging, but may also be determined during surgical exploration.[123-126] The scale involves a visual quantification of the extent and location of peritoneal disease, scored as 0 to 3 in each of the 13 regions of the abdominal cavity. Regions 0 through 8 are oriented clockwise in the abdominal cavity, while regions 9 through 12 represent the proximal and distal jejunum and the proximal and distal ileum. The potential of a successful CRS and IPCT can be predicted using PCI since factors such as tumor distribution in the abdominal and pelvic regions and lesion size scoring are standardized to

Version 2.2026 © 2026 National Comprehensive Cancer Network© (NCCN©), All rights reserved. NCCN Guidelines® and this illustration may not be reproduced in any form without the express written permission of NCCN.

PLEASE NOTE that use of this NCCN Content is governed by the End-User License Agreement, and you MAY NOT distribute this Content or use it with any artificial intelligence model or tool.
Printed by Máximo López Chenlo on 5/4/2026 6:12:29 PM. Copyright © 2026 National Comprehensive Cancer Network, Inc. All Rights Reserved.

quantitatively measure carcinomatosis burden.[124,127] A lower PCI score (10–20) tends to indicate a better prognosis and treatment outcome given the limited spread of disease whereas higher scores (20–30, >30) generally indicate extensive disease spread, which will limit therapeutic success of CRS and IPCT.[124] Generally, a PCI score of ≤20 indicates suitability for CRS and IPCT in patients with PC originating from a GI primary malignancy.[128] While PCI correlates with the ability to achieve a complete CRS, it is not associated with survival as long as a complete CRS can be achieved.[129]

Completeness of cytoreduction (CC) grades are standardly listed as follows: CC-0, no visible residual disease; CC-1, residual disease up to 2.5 mm; CC-2, residual disease up to 2.5 cm; CC-3, residual disease >2.5 cm. The benefit and effectiveness of HIPEC hinges on the extent of CRS since complete microscopic tumor removal (CC-0) is ideal due to the limited penetration ability of IPCT.[108,118] CC is a strong predictor of long-term patient outcome following CRS/IPCT since a higher CC score is associated with more residual nodules remaining in the affected area.[130] A subset of patients with AA in a study evaluating long-term outcomes of patients with different mucinous cellular profiles revealed that patients with CC 0/1 CRS to control primary tumor pathologies exhibited significant differences in relapse-free survival (RFS) and OS based alone on the cellularity of mucinous deposits within the peritoneal cavity.[115]

CRS/IPCT for Recurrent Disease – Repeat Procedures

The need for more than a single CRS/IPCT procedure may be considered in patients who experience incomplete CRS or recurrent peritoneal metastases.[111,131] An analysis of patients with peritoneal recurrences after initial treatment for LAMN who underwent either one or two CRS/HIPEC procedures revealed a significantly longer median OS for the patients who underwent two procedures versus one procedure (227.1 vs. 54.5 months; $P < .0001$), along with an association of longer time between the two procedures and improved OS.[132]

A comparison of the outcomes of repeated CRS for patients with AC, featuring 102 patients who had repeat procedures due to recurrences, found that repeat CRS in higher volume peritoneal areas provided notable benefits, especially when the primary neoplasms were of appendiceal epithelial origin.[131] Compared to 360 patients who only required a single procedure, the 102 patients who underwent multiple procedures had a significantly higher PCI score (24.0 vs. 29.5; $P < .001$). Notably, PCI scores were much lower for the second CRS/HIPEC procedure compared to the first in the repeat group (15 vs. 29.5; $P < .001$). Receiving multiple CRS/HIPEC procedures for patients with recurrence tends to lead to improved outcomes in this study, as well as in other previous studies with similar conclusions.[131,133-136] If AC recurrence is seen in patients, CRS/IPCT is generally considered if symptomatic disease is present and/or low-grade tumors are found, preferably for someone with a longer disease-free interval.

As with any medical procedure, especially one as invasive and impactful as CRS/HIPEC, substantial risks exist that must be considered by the patient and clinician. In this study, a second procedure may compound a patient's comorbidities. This is crucial to the success of an additional procedure as recovery is heavily impacted by treatment complications, requiring a delicate balance of symptom-driven necessity for surgery and patient desire to endure the surgery and recovery processes.[111,132,137] For cases in which complete CRS is not possible, palliative CRS ± HIPEC can be considered an option to treat symptomatic disease, such as bowel obstruction.

Chemotherapeutic Agents Used in IPCT

Mitomycin C (MMC) is the mostly commonly used IPCT agent.[118,138] Oxaliplatin is an option that is less preferred and may be avoided if

Version 2.2026 © 2026 National Comprehensive Cancer Network© (NCCN©), All rights reserved. NCCN Guidelines® and this illustration may not be reproduced in any form without the express written permission of NCCN.

PLEASE NOTE that use of this NCCN Content is governed by the End-User License Agreement, and you MAY NOT distribute this Content or use it with any artificial intelligence model or tool.
Printed by Máximo López Chenlo on 5/4/2026 6:12:29 PM. Copyright © 2026 National Comprehensive Cancer Network, Inc. All Rights Reserved.

patients are currently receiving or will receive systemic oxaliplatin in their treatment plan.[139] A randomized 10-year follow-up study compared the OS and DFS of 121 patients with AC who underwent HIPEC for PC, receiving either MMC or oxaliplatin as the chemotherapeutic component.[140] The 10-year OS for MMC and oxaliplatin groups were 47.5% and 50.4% (P = .83) and the 10-year PFS values were 45.2% and 50.4% (P = .95), respectively. Other studies have evaluated patient survival after CRS/HIPEC with different chemotherapy agents for treatment of AC and PMP. Five-year OS after MMC HIPEC are appreciable, with values ranging from 53% to 97%, depending on the origin of the tumor, dose of the chemotherapy, co-treatment with other chemotherapies, and duration of HIPEC treatment.[136,141-146]

Other IPCT regimens have been studied including oxaliplatin/fluorouracil/leucovorin (LV), cisplatin/MMC, cisplatin alone, and cisplatin/doxorubicin[114,147]; however, these are not currently recommended in the NCCN Guidelines for treatment of PC in AC.

Complications Associated with CRS/IPCT

Although the therapeutic value is compelling in eligible patients, CRS and IPCT come with complications that are both linked to morbidities and directly to the treatments themselves. Some of the most common complications linked to IPCT/HIPEC are hematologic toxicities, systemic infections, GI toxicities, and cardiovascular toxicities.[148] A long-term follow-up study of patients with peritoneal metastases revealed that CRS and HIPEC treatments led to 32.4-month median survival values, but with a significant incidence of comorbidities.[149] A study reporting on the association between risk factors and infection outcomes that featured 12 patients with AC without PMP and 34 patients with PMP who underwent CRS and HIPEC showed that 43% of all patients involved experienced infections at the surgical site, respiratory tract, urinary tract, and sepsis.[150] The critical finding in this study, the higher the burden, the higher the chance of post-procedure complications, highlights the need for personalized treatment planning for patients. Some models have been developed to help predict severe postoperative complications following CRS/IPCT; these models may aid with patient selection and help providers anticipate and respond proactively to likely complications.[151-153]

Systemic Therapy for Resectable Disease

Neoadjuvant Chemotherapy

While there is a body of literature investigating whether there is a benefit for neoadjuvant chemotherapy prior to CRS/IPCT, the evidence has been mixed as to whether this approach offers a benefit, causes worse outcomes, or causes mixed outcomes.[154] Elevated CEA levels may predict a survival benefit from neoadjuvant therapy.[155]

Several studies have shown a potential benefit to neoadjuvant therapy before CRS/IPCT.[121,156-161] An analysis of prospectively collected data showed that 29% of 34 patients treated with preoperative systemic therapy had a complete or near-complete histologic response.[157] Patients receiving preoperative therapy also had a lower PCI, required fewer resections, and achieved complete cytoreduction more frequently compared to patients who did not receive preoperative chemotherapy. Another study of 178 patients with moderately or poorly differentiated AC similarly showed that 47.1% of the patients who received neoadjuvant chemotherapy had a radiographic response and that stable or responsive disease was associated with improved OS.[121] A third study reported a potential survival benefit with neoadjuvant systemic therapy for patients with signet ring cell histology (94%, 67%, and 22% survival at 1, 2, and 3 years with neoadjuvant systemic therapy compared to 43%, 14%, and 14% survival without neoadjuvant therapy; P = .028)[158] A similar benefit was not seen among patients with high- or low-grade tumors without signet ring histology. Furthermore, a small retrospective review comparing a total

Version 2.2026 © 2026 National Comprehensive Cancer Network© (NCCN©), All rights reserved. NCCN Guidelines® and this illustration may not be reproduced in any form without the express written permission of NCCN.

PLEASE NOTE that use of this NCCN Content is governed by the End-User License Agreement, and you MAY NOT distribute this Content or use it with any artificial intelligence model or tool.
Printed by Máximo López Chenlo on 5/4/2026 6:12:29 PM. Copyright © 2026 National Comprehensive Cancer Network, Inc. All Rights Reserved.

neoadjuvant therapy (TNT) approach prior to CRS/IPCT compared to a "sandwich" pre-/postoperative approach concluded that TNT showed improved OS and RFS.[159]

Other studies have shown either no benefit or even worse outcomes with neoadjuvant therapy prior to CRS/IPCT.[117,162-168] A retrospective review of 803 patients with AC showed no difference in OS, but worse RFS (14 vs. 22 months; $P = .007$) with neoadjuvant chemotherapy before CRS/IPCT.[162] Another retrospective analysis identified preoperative chemotherapy as a multivariate negative predictor of survival following CRS/HIPEC for both low-grade ($P = .04$) and high-grade ($P = .0064$) lesions.[165] Similarly, a multicenter retrospective cohort study of patients with LAMN treated with CRS/HIPEC concluded that those who received perioperative systemic therapy had worse outcomes compared to those who did not.[167] OS and RFS were 70.2 and 38.0 months with perioperative systemic therapy, compared to 104.3 and 84.9 months without ($P < .001$). As a fourth example, a retrospective review of 126 patients with high-grade disease that was treated with CRS/HIPEC also concluded that neoadjuvant therapy was associated with decreases in OS and DFS and no differences in disease burden, cytoreduction, or recurrence patterns.[168] Five-year OS was 24.2% versus 5% ($P = .017$) and 5-year DFS was 18.6% versus 5.7% ($P = .048$).

Based on these mixed data that show a potential benefit in select clinical situations, the NCCN Panel recommends that neoadjuvant systemic therapy may be considered prior to CRS/IPCT for recurrence of high-risk disease with no previous CRS, and is a preferred approach for AA, GCA, or UC-NOS with metastatic disease in the peritoneum only. Perioperative therapy is not recommended for patients with LAMN or HAMN without high-grade peritoneal deposits based on data showing lack of benefit in this setting.

Adjuvant Chemotherapy

There are some studies on adjuvant therapy for appendiceal neoplasms and cancers that indicate that it may improve outcomes for certain patients following surgery for localized disease or CRS/IPCT, although data are limited and mixed.[9,154,169-173]

Two studies of the NCDB have investigated the role of adjuvant chemotherapy following surgery for localized disease.[9,172] One such study of 11,871 patients with appendiceal neoplasms and cancers supported the use of adjuvant therapy for these patients, showing a benefit with adjuvant therapy in both mucinous and nonmucinous histologies.[9] For stage I to III disease, in multivariate modeling, adjuvant chemotherapy improved OS for both mucinous (HR, 0.78; 95% CI, 0.68–0.89; $P = .0002$) and nonmucinous histologies (HR, 0.83; 95% CI, 0.74–0.94; $P = .002$). However, a more recent study of the NCBD showed differences in response to adjuvant therapy following RHC for non-metastatic mucinous and nonmucinous histologies.[172] For nonmucinous histologies, adjuvant chemotherapy significantly improved OS for stage II and III disease, while for mucinous histologies, adjuvant therapy was associated with worse outcomes for stage I/II disease and no significant association with OS for stage III disease.

Several studies have looked at adjuvant treatment following RHC for GCA of the appendix, specifically.[174-176] One such study, an 11-year analysis of 867 patients with stage I–III GCA who underwent RHC identified within the NCDB, compared those who received adjuvant therapy to those who did not.[175] Patients who received adjuvant therapy were more likely to be of younger age, male sex, and had a higher proportion of poorly/undifferentiated grade (27 vs. 5%; $P < .001$), T4 tumors (35 vs. 11%; $P < .001$), and lymph node-positive disease (45 vs. 7%; $P < .001$) than patients who did not receive adjuvant therapy. After excluding patients without follow-up data, a survival advantage for adjuvant therapy

Version 2.2026 © 2026 National Comprehensive Cancer Network© (NCCN©), All rights reserved. NCCN Guidelines® and this illustration may not be reproduced in any form without the express written permission of NCCN.

PLEASE NOTE that use of this NCCN Content is governed by the End-User License Agreement, and you MAY NOT distribute this Content or use it with any artificial intelligence model or tool.
Printed by Máximo López Chenlo on 5/4/2026 6:12:29 PM. Copyright © 2026 National Comprehensive Cancer Network, Inc. All Rights Reserved.

was detected only after stratification for lymph node-positive disease (*P* = .007). On Cox proportional hazard regression, adjuvant therapy demonstrated an independent association with improved OS (HR, 0.24; 95% CI, 0.084–0.683; *P* = .007).

Other studies have investigated the role of adjuvant therapy following CRS/IPCT. A retrospective study of 103 patients with AA identified 68 who had a complete cytoreduction (CRS 0-1), of which 26 received adjuvant chemotherapy.[169] The most commonly used regimens were capecitabine, CAPEOX (capecitabine/oxaliplatin), and FOLFOX (fluorouracil/LV/oxaliplatin). The median OS for patients with non-low-grade and well-differentiated tumors who received adjuvant chemotherapy after complete cytoreduction was 9.03 years, compared to 2.88 years for patients who did not receive adjuvant chemotherapy (*P* = .02). For patients with low-grade disease, this benefit with adjuvant therapy was not observed. Another retrospective review matched 22 patients with low-grade AC with MCP treated with CRS/HIPEC and perioperative systemic therapy with those who received CRS/HIPEC alone.[177] Median OS was 107 months for those who received perioperative systemic therapy compared to 72 months for those who did not (*P* = .46). Adjuvant systemic therapy was specifically associated with longer PFS (13.6 months) when compared to neoadjuvant therapy (6.8 months, *P* < .01). A third retrospective cohort study that compared survival of 77 patients with stage IV high-grade mucinous AC who were treated with CRS/HIPEC and adjuvant therapy to 103 patients who did not receive adjuvant therapy did not show a benefit.[173] Median OS did not significantly differ with adjuvant chemotherapy (53 months with adjuvant chemotherapy vs. 75 months without), even after adjusting for cofounding variables. Adjuvant chemotherapy regimens used in this study included single-agent fluoropyrimidine and oxaliplatin-based, irinotecan-based, and bevacizumab-containing regimens.

Based on these mostly positive data, adjuvant systemic therapy with FOLFOX, CAPEOX, fluorouracil/LV, or capecitabine may be considered after RHC or CRS/IPCT for select patients. When adjuvant therapy is being considered, FOLFOX or CAPEOX are preferred over a single-agent fluoropyrimidine.

Palliative Systemic Therapy for Advanced or Metastatic Disease

Data supporting systemic therapy for advanced appendiceal neoplasms and cancers are limited and recommended therapies are, therefore, largely extrapolated from those studied in metastatic CRC. The goal of therapy is considered to be palliative in these settings. For some patients with advanced appendiceal neoplasms, particularly those with LAMN or HAMN, chemotherapy may cause significant side effects without clear benefit and should be used judiciously. Patients with positive lymph nodes may derive the most benefit from systemic therapy.[178] The following sections discuss what data are available for systemic therapy in advanced appendiceal neoplasms and cancers and the Panel recommendations for treatment.

Systemic Therapy for LAMN or HAMN

A randomized crossover trial included 24 patients with metastatic low-grade mucinous appendiceal tumors who were not candidates for complete CRS and had radiographic imaging demonstrating the presence of mucinous PC.[179] Patients on this trial were randomized to either 6 months of observation followed by 6 months of chemotherapy, or vice versa. Chemotherapy regimens that were used on the study varied, with most (63%) receiving single-agent fluorouracil or capecitabine; 13% receiving doublet chemotherapy [FOLFOX or FOLFIRI (fluorouracil/LV/irinotecan)]; and 21% receiving bevacizumab in combination with chemotherapy. Of the 15 patients who were available to be evaluated for the primary endpoint, tumor growth while receiving

Version 2.2026 © 2026 National Comprehensive Cancer Network© (NCCN©), All rights reserved. NCCN Guidelines® and this illustration may not be reproduced in any form without the express written permission of NCCN.

PLEASE NOTE that use of this NCCN Content is governed by the End-User License Agreement, and you MAY NOT distribute this Content or use it with any artificial intelligence model or tool.
Printed by Máximo López Chenlo on 5/4/2026 6:12:29 PM. Copyright © 2026 National Comprehensive Cancer Network, Inc. All Rights Reserved.

chemotherapy increased 8.4% from baseline and was not significantly different from tumor growth during observation (4.0%; *P* = .26). Of the 18 patients who received chemotherapy on the trial, none had an objective response and there was no significant difference in median OS between the observation-first group and the treatment-first group (76.0 vs. 53.2 months; *P* = .48). Patient-reported quality of life metrics identified significantly worse fatigue, peripheral neuropathy, and financial difficulty during treatment compared with observation.

A study of the NCDB reported similar findings in 639 patients with mucinous, grade 1, stage IV AC who were either treated with systemic chemotherapy or were not.[180] Those who were treated with chemotherapy were found to have similar OS compared to those who did not receive chemotherapy after adjusting with a Cox proportional hazards model (HR, 1.1; 95% CI, 0.82–1.40). Another study of the NCDB reached the same conclusion for well-differentiated mucinous appendiceal neoplasms.[9]

While these studies demonstrated a lack of clinical benefit from systemic chemotherapy in patients with LAMN, some members of the NCCN Panel have occasionally seen benefit from treating patients with systemic chemotherapy in this setting. Therefore, the Panel considers a trial of palliative systemic therapy to be a reasonable option for patients with metastatic LAMN or HAMN who are not candidates for surgery. Single-agent fluoropyrimidine, FOLFOX, or FOLFIRI may be considered, with or without bevacizumab. Based on the previously discussed trial results, prolonged exposure to chemotherapy is not recommended for patients with LAMN or HAMN who are not demonstrating a clinical response.

Systemic Therapy for Appendiceal Carcinomas (AA, GCA, or UC-NOS)

In contrast with the data for LAMN and HAMN, several studies have shown benefit for systemic therapy in patients with higher-risk AC.[9,181-183]

A single-center, observational study assessed the activity of systematic therapy with FOLFOX-4 in 20 patients with unresectable or relapsed PMP from appendiceal origin.[184] The overall objective response rate (primary endpoint) was 20%. The median PFS and OS were 8 months (95% CI, 0–16.8 months) and 26.2 months (95% CI, 18.1–34.3 months), respectively. In this study, four individuals reported grade ≥3 AEs, including neutropenia (*n* = 3) and fatigue (*n* = 1). Other retrospective reviews have also identified FOLFOX and/or FOLFIRI as safe and effective options for treatment of unresectable AC.[181,185-187]

A retrospective review of 42 patients with high-grade AA with peritoneal metastases compared those receiving doublet chemotherapy (FOLFOX, CAPEOX, or FOLFIRI) to those receiving triplet chemotherapy [FOLFIRINOX or FOLFOXIRI (fluorouracil/LV/oxaliplatin/irinotecan)] as first-line therapy.[188] Between the doublet and triplet groups, median OS was not significantly different (32.2 vs. 23.5 months; *P* = .38) and remained non-significantly different within a 1:1 propensity-matched cohort analysis. RFS after CRS/HIPEC and PFS were also similar between the groups.

A prospective, single-arm study of 15 patients with relapsed PMP of appendiceal origin treated with capecitabine and bevacizumab concluded that the combination was safe and effective for this disease.[189] After a median follow-up of 12 months, median PFS was 8.2 months and 12-month OS was 91%. All tumor samples except one had *KRAS* mutations, and *GNAS* mutations were correlated with a significantly shorter median PFS as compared to *GNAS* wild-type (*P* < .007). A retrospective review of 130 patients with unresectable appendiceal tumors also showed an improvement in OS (*P* = .03) and PFS (*P* = .047) with the addition of bevacizumab to chemotherapy.[190]

Due to the limited data supporting systemic therapy for unresectable or metastatic appendiceal carcinomas, many of the recommendations are

Version 2.2026 © 2026 National Comprehensive Cancer Network© (NCCN©), All rights reserved. NCCN Guidelines® and this illustration may not be reproduced in any form without the express written permission of NCCN.

PLEASE NOTE that use of this NCCN Content is governed by the End-User License Agreement, and you MAY NOT distribute this Content or use it with any artificial intelligence model or tool.
Printed by Máximo López Chenlo on 5/4/2026 6:12:29 PM. Copyright © 2026 National Comprehensive Cancer Network, Inc. All Rights Reserved.

extrapolated from CRC. First-line therapy may include a fluoropyrimidine-based chemotherapy (CAPEOX, FOLFOX, FOLFIRI, or FOLFIRINOX) alone or in combination with bevacizumab. For patients for whom intensive therapy is not recommended, capecitabine or fluorouracil alone may be used, with or without bevacizumab. Based on data suggesting that anti-EGFR therapy does not improve OS for *KRAS* wild-type AA,[191] cetuximab or panitumumab are not recommended as first-line options, except when given in combination with encorafenib for treatment of *BRAF V600E* tumors. As an extrapolation of the BREAKWATER trial for metastatic CRC,[192] and data that *BRAF* V600E-mutant AA responds to *BRAF*-targeted therapy,[65] FOLFOX and encorafenib in combination with cetuximab or panitumumab may be given as first-line therapy for *BRAF V600E* AC. While dMMR/MSI-H or *POLE/POLD1* mutations with ultra-hypermutated phenotype are rare in AC,[191] checkpoint inhibitors are an option for any line of therapy in these patients.

For subsequent lines of therapy, the chemotherapy regimens recommended as first-line options may be given as subsequent line, if not given previously. In addition, as an extrapolation from CRC, many of the therapies recommended as options for non-first-line therapy in CRC may be considered as second- and subsequent-line options for AC. These options include targeted therapies for *BRAF* V600E, *KRAS* G12C, HER2 positivity, and *NTRK* or *RET* gene fusions. While there are data to suggest that the use of cetuximab or panitumumab have no impact on OS in *RAS* wild-type tumors,[191] the Panel does not consider the evidence strong enough to preclude use of these therapies; therefore, they may be considered in combination with chemotherapy for *KRAS/NRAS/BRAF* wild-type AC in later lines of therapy.

There are several other systemic therapy regimens that have also been studied for unresectable or metastatic ACs. A phase II study of 40 patients with advanced unresectable PMP studied a combination of systemic MMC and capecitabine.[193] Of 39 assessable patients on this trial, 38% showed benefit from the combination, including two patients with disease that was converted to resectability with potentially curable CRS. Taxane-based chemotherapy has also been of interest for treatment of advanced AA based on molecular features that distinguish it from advanced CRC, notably the rarity of *APC* mutation.[51] A single-center retrospective study looked at the efficacy of taxane chemotherapy on a cohort of 13 patients with metastatic AA.[194] Median OS was 8.8 months and, of 10 evaluable patients, there were three with disease response, four with stable disease, and three with progressive disease. A recent phase II study evaluated the efficacy and safety of atezolizumab in combination with bevacizumab in advanced, unresectable AA.[195] Of the 16 patients treated with this combination, 100% experienced disease control (1 partial response, 15 stable disease), with a median PFS of 18.3 months. Finally, another recent study studied the efficacy of the CDK4/6 inhibitor, palbociclib, in 16 patients with *GNAS*-mutant cancers with peritoneal mucinous carcinomatosis, 13 of those with appendiceal origin.[196] Fifty percent of evaluable patients had stable disease after 12 months of treatment and median survival had not yet been reached at 17.6 months. While the NCCN Panel finds these data encouraging, they do not consider the current evidence for these regimens to be strong enough to recommend at this time.

Post-Treatment Surveillance

Due to the rarity of the disease and the lack of data on optimal surveillance schedules for appendiceal neoplasms and cancers, the NCCN recommendations for post-treatment surveillance are extrapolated from those recommended for colon cancer, with some adjustments based on the unique biology and recurrence patterns of appendiceal neoplasms and cancers.

Version 2.2026 © 2026 National Comprehensive Cancer Network© (NCCN©), All rights reserved. NCCN Guidelines® and this illustration may not be reproduced in any form without the express written permission of NCCN.

PLEASE NOTE that use of this NCCN Content is governed by the End-User License Agreement, and you MAY NOT distribute this Content or use it with any artificial intelligence model or tool.
Printed by Máximo López Chenlo on 5/4/2026 6:12:29 PM. Copyright © 2026 National Comprehensive Cancer Network, Inc. All Rights Reserved.

LAMN or HAMN without high-risk peritoneal deposit have a more indolent disease course and, therefore, do not require as intensive surveillance compared to higher-risk tumors. Based on its indolent nature, LAMN and HAMN recurrences may occur later than other appendiceal tumors, necessitating a longer duration of surveillance. A retrospective review of 217 patients with localized LAMN reported a median time to recurrence of 14.4 months,[197] while another retrospective study of noninvasive mucinous appendiceal neoplasms, with and without peritoneal dissemination, reported LAMN that recurred at 57 and 68 months post-treatment.[198] Based on these later recurrences for LAMN and HAMN, a longer surveillance interval of 10 years is recommended for both resected localized disease and resected metastatic disease.

For resected localized LAMN or HAMN, NCCN recommends a history and physical exam, including measurement of tumor markers such as CEA, CA 19-9, and CA-125, every 6 to 12 months for 2 years, then annually for up to a total of 10 years. CT or MRI of the abdomen and pelvis should be performed every 6 to 12 months for 2 years from the date of surgery, then every 12 to 24 months for up to a total of 10 years. Surveillance recommendations are similar for resected metastatic LAMN or HAMN, except that physical exam should be at a frequency of every 6 months for the first 2 years and imaging should include the chest, abdomen, and pelvis and occur every 6 months for the first 2 years post-surgery, then every 12 months up to a total of 10 years. FDG-PET/CT is not indicated for surveillance of LAMN or HAMN, and colonoscopy need only be performed to look for additional primary cancers if no preoperative colonoscopy was done.

LAMN may be especially unlikely to recur. A study of 114 patients who underwent surgical resection of localized LAMN determined that after a mean follow-up duration of 4.7 years, no patients had experienced tumor recurrence.[199] Another study of 217 patients with localized LAMN reported a recurrence rate of just 3.2%, with many of the recurrent cases showing higher-risk features such as perforation or extra-appendiceal acellular mucin.[197] Based on this, it may be appropriate to forgo surveillance for patients with completely resected LAMN confined to the appendix without high-risk features.

AC histologies such as AA, GCA, or UC-NOS carry a higher risk of recurrence and, therefore, prompt a more intensive post-treatment surveillance schedule.[200] However, since recurrences tend to occur earlier than for LAMN or HAMN, 5 years is adequate for the surveillance period. For resected localized disease, history and physical examination, including measurement of CEA, CA 19-9 and CA-125, should be performed every 3-6 months for 2 years, then every 6 months for a total of 5 years. After the first 2 years, tumor markers may be measured every 6 to 12 months. CT of the chest, abdomen, and pelvis should be performed every 6 to 12 months from the date of surgery for a total of 5 years. For resected metastatic disease, history and physical exam, including measurement of CEA, CA 19-9 and CA-125, should be performed every 3 to 6 months for 2 years, then every 6 months for a total of 5 years. CT of the chest, abdomen, and pelvis should be performed every 3 to 6 months for 2 years, then every 6 to 12 months for a total of 5 years. FDG-PET/CT is not indicated for surveillance of AA, GCA, or UC-NOS, and colonoscopy need only be performed to look for additional primary cancers if no preoperative colonoscopy was done.

Survivorship

Based on the rarity of appendiceal neoplasms and cancers, there is a dearth of data regarding survivorship for this disease. The Panel recommendations for survivorship are largely extrapolated from the NCCN Guidelines for Colon Cancer, although some special considerations may be needed for survivors experiencing long-term effects of CRS and/or IPCT for peritoneal metastases.[201,202] This section will provide an overview

Version 2.2026 © 2026 National Comprehensive Cancer Network© (NCCN©), All rights reserved. NCCN Guidelines® and this illustration may not be reproduced in any form without the express written permission of NCCN.

PLEASE NOTE that use of this NCCN Content is governed by the End-User License Agreement, and you MAY NOT distribute this Content or use it with any artificial intelligence model or tool.
Printed by Máximo López Chenlo on 5/4/2026 6:12:29 PM. Copyright © 2026 National Comprehensive Cancer Network, Inc. All Rights Reserved.

of the Panel recommendations for survivorship; for more detailed information, see the *Survivorship* section in the NCCN Guidelines for Colon Cancer (available at www.NCCN.org).

The Panel recommends that a prescription for survivorship and transfer of care to the primary care physician be written.[203] The oncologist and primary care provider should have defined roles in the surveillance period, with roles communicated to the patient. Other recommendations for survivors of GI cancers include monitoring for late or long-term sequelae of treatment, such as oxaliplatin-induced peripheral neuropathy, fatigue, pain, sexual dysfunction, and emotional or social distress.[204-208] Specific management interventions to address these and other side effects are described in a review.[209] Disease preventive measures, such as immunizations; early disease detection through periodic screening for second primary cancers (eg, breast, cervical, or prostate cancers); and routine good medical care and monitoring are recommended. The NCCN Guidelines for Survivorship (available at www.NCCN.org) provide screening, evaluation, and treatment recommendations for common consequences of cancer and cancer treatment to aid health care professionals who work with survivors of adult-onset cancer in the post-treatment period, including those in specialty cancer survivor clinics and primary care practices.

Summary

Appendiceal neoplasms and cancers are rare tumors of the digestive system, often found incidentally on surgical specimens following appendectomy. Treatment recommendations depend on the pathologic type, with some tumors (ie, LAMN or HAMN) presenting a lower risk of progression or recurrence than other pathologic types. For localized disease, surgery via a negative-margin appendectomy with or without cecal cuff resection is often curative, although adjuvant chemotherapy may be considered for higher-risk pathologies. Peritoneal disease will often require CRS, with or without IPCT, or palliative measures if complete CRS is not possible. Cases with a low-grade primary tumor histology but higher-grade peritoneal metastasis should be treated like other high-risk pathologies. The role of neoadjuvant or adjuvant therapy is poorly defined but may be recommended depending on the specific clinical scenario. Treatment for extraperitoneal metastatic disease is palliative and may include a combination of surgery, systemic therapy, clinical trial, or best supportive care.

Version 2.2026 © 2026 National Comprehensive Cancer Network© (NCCN©), All rights reserved. NCCN Guidelines® and this illustration may not be reproduced in any form without the express written permission of NCCN.

PLEASE NOTE that use of this NCCN Content is governed by the End-User License Agreement, and you MAY NOT distribute this Content or use it with any artificial intelligence model or tool.
Printed by Máximo López Chenlo on 5/4/2026 6:12:29 PM. Copyright © 2026 National Comprehensive Cancer Network, Inc. All Rights Reserved.

References

1. Ruoff C, Hanna L, Zhi W, et al. Cancers of the appendix: review of the literatures. ISRN Oncol 2011;2011:728579. Available at: https://www.ncbi.nlm.nih.gov/pubmed/22084738.

2. Xie X, Zhou Z, Song Y, et al. The Management and Prognostic Prediction of Adenocarcinoma of Appendix. Sci Rep 2016;6:39027. Available at: https://www.ncbi.nlm.nih.gov/pubmed/27982068.

3. McCusker ME, Cote TR, Clegg LX, Sobin LH. Primary malignant neoplasms of the appendix: a population-based study from the surveillance, epidemiology and end-results program, 1973-1998. Cancer 2002;94:3307–3312. Available at: https://www.ncbi.nlm.nih.gov/pubmed/12115365.

4. Marmor S, Portschy PR, Tuttle TM, Virnig BA. The rise in appendiceal cancer incidence: 2000-2009. J Gastrointest Surg 2015;19:743–750. Available at: https://www.ncbi.nlm.nih.gov/pubmed/25560182.

5. Singh H, Koomson AS, Decker KM, et al. Continued increasing incidence of malignant appendiceal tumors in Canada and the United States: A population-based study. Cancer 2020;126:2206–2216. Available at: https://www.ncbi.nlm.nih.gov/pubmed/32101643.

6. Holowatyj AN, Washington MK, Goldberg RM, Murphy CC. Birth Cohort Effects in Appendiceal Adenocarcinoma Incidence Across the United States. Ann Intern Med 2025;178:957–962. Available at: https://www.ncbi.nlm.nih.gov/pubmed/40489784.

7. Salazar MC, Canavan ME, Chilakamarry S, et al. Appendiceal Cancer in the National Cancer Database: Increasing Frequency, Decreasing Age, and Shifting Histology. J Am Coll Surg 2022;234:1082–1089. Available at: https://www.ncbi.nlm.nih.gov/pubmed/35703801.

8. Liu T, Mi J, Wang Y, et al. Establishment and validation of the survival prediction risk model for appendiceal cancer. Front Med (Lausanne) 2022;9:1022595. Available at: https://www.ncbi.nlm.nih.gov/pubmed/36388937.

9. Asare EA, Compton CC, Hanna NN, et al. The impact of stage, grade, and mucinous histology on the efficacy of systemic chemotherapy in adenocarcinomas of the appendix: Analysis of the National Cancer Data Base. Cancer 2016;122:213–221. Available at: https://www.ncbi.nlm.nih.gov/pubmed/26506400.

10. Gibbs T, Washington MK, Eng C, et al. Histologic and Racial/Ethnic Patterns of Appendiceal Cancer among Young Patients. Cancer Epidemiol Biomarkers Prev 2021;30:1149–1155. Available at: https://www.ncbi.nlm.nih.gov/pubmed/33795212.

11. Chicago Consensus Working G. The Chicago Consensus on peritoneal surface malignancies: Management of appendiceal neoplasms. Cancer 2020;126:2525–2533. Available at: https://www.ncbi.nlm.nih.gov/pubmed/32282073.

12. Godfrey EL, Mahoney F, Bansal VV, et al. Consensus guideline for the management of patients with appendiceal tumors, part 1: Appendiceal tumors without peritoneal involvement. Cancer 2025;131:e35867. Available at: https://www.ncbi.nlm.nih.gov/pubmed/40558045.

13. Godfrey EL, Mahoney F, Bansal VV, et al. Consensus guideline for the management of patients with appendiceal tumors, part 2: Appendiceal tumors with peritoneal involvement. Cancer 2025;131:e35874. Available at: https://www.ncbi.nlm.nih.gov/pubmed/40558065.

14. PubMed Overview. Available at: https://pubmed.ncbi.nlm.nih.gov/about/. Accessed November 21, 2025.

15. Freedman-Cass DA, Fischer T, Alpert AB, et al. The Value and Process of Inclusion: Using Sensitive, Respectful, and Inclusive Language and Images in NCCN Content. J Natl Compr Canc Netw 2023;21:434–441. Available at: https://www.ncbi.nlm.nih.gov/pubmed/37156485.

16. Janczewski LM, Browner AE, Cotler JH, et al. Survival outcomes used to validate version 9 of the American Joint Committee on Cancer staging system for appendiceal cancer. CA Cancer J Clin 2023;73:590–596. Available at: https://www.ncbi.nlm.nih.gov/pubmed/37358310.

Version 2.2026 © 2026 National Comprehensive Cancer Network© (NCCN©), All rights reserved. NCCN Guidelines® and this illustration may not be reproduced in any form without the express written permission of NCCN.

PLEASE NOTE that use of this NCCN Content is governed by the End-User License Agreement, and you MAY NOT distribute this Content or use it with any artificial intelligence model or tool.
Printed by Máximo López Chenlo on 5/4/2026 6:12:29 PM. Copyright © 2026 National Comprehensive Cancer Network, Inc. All Rights Reserved.

17. Connor SJ, Hanna GB, Frizelle FA. Appendiceal tumors: retrospective clinicopathologic analysis of appendiceal tumors from 7,970 appendectomies. Dis Colon Rectum 1998;41:75–80. Available at: https://www.ncbi.nlm.nih.gov/pubmed/9510314.

18. Graham RP, Williams NP, West KA. Primary epithelial tumours of the appendix in a black population: a review of cases. World J Gastroenterol 2009;15:1472–1474. Available at: https://www.ncbi.nlm.nih.gov/pubmed/19322920.

19. Crea N, Pata G, Di Betta E, et al. High incidence of appendix carcinoid tumors among candidates for bariatric surgery: diagnostic and therapeutic implications. Obes Surg 2011;21:151–156. Available at: https://www.ncbi.nlm.nih.gov/pubmed/20186577.

20. Leonards LM, Pahwa A, Patel MK, et al. Neoplasms of the Appendix: Pictorial Review with Clinical and Pathologic Correlation. Radiographics 2017;37:1059–1083. Available at: https://www.ncbi.nlm.nih.gov/pubmed/28598731.

21. Gundogar O, Kimiloglu E, Komut N, et al. Evaluation of appendiceal mucinous neoplasms with a new classification system and literature review. Turk J Gastroenterol 2018;29:533–542. Available at: https://www.ncbi.nlm.nih.gov/pubmed/30260774.

22. Hajiran A, Baker K, Jain P, Hashmi M. Case of an appendiceal mucinous adenocarcinoma presenting as a left adnexal mass. Int J Surg Case Rep 2014;5:172–174. Available at: https://www.ncbi.nlm.nih.gov/pubmed/24568943.

23. Hatch QM, Gilbert EW. Appendiceal Neoplasms. Clin Colon Rectal Surg 2018;31:278–287. Available at: https://www.ncbi.nlm.nih.gov/pubmed/30186049.

24. Patel SH, Bihlmeyer S, Eggenberger JC, et al. Locally advanced perforated appendiceal cancer: Case report and review. Clin Case Rep 2022;10:e05349. Available at: https://www.ncbi.nlm.nih.gov/pubmed/35169467.

25. Persaud T, Swan N, Torreggiani WC. Giant mucinous cystadenoma of the appendix. Radiographics 2007;27:553–557. Available at: https://www.ncbi.nlm.nih.gov/pubmed/17374868.

26. Carr NJ, McCarthy WF, Sobin LH. Epithelial noncarcinoid tumors and tumor-like lesions of the appendix. A clinicopathologic study of 184 patients with a multivariate analysis of prognostic factors. Cancer 1995;75:757–768. Available at: https://www.ncbi.nlm.nih.gov/pubmed/7828125.

27. Fackche N, Schmocker RK, Kubi B, et al. The Utility of Preoperative Tumor Markers in Peritoneal Carcinomatosis from Primary Appendiceal Adenocarcinoma: an Analysis from the US HIPEC Collaborative. J Gastrointest Surg 2021;25:2908–2919. Available at: https://www.ncbi.nlm.nih.gov/pubmed/33634422.

28. Lansom J, Alzahrani N, Liauw W, Morris DL. Cytoreductive Surgery and Hyperthermic Intraperitoneal Chemotherapy for Pseudomyxoma Peritonei and Appendix Tumours. Indian J Surg Oncol 2016;7:166–176. Available at: https://www.ncbi.nlm.nih.gov/pubmed/27065707.

29. Yousef A, Yousef M, Zeineddine MA, et al. Serum Tumor Markers and Outcomes in Patients With Appendiceal Adenocarcinoma. JAMA Netw Open 2024;7:e240260. Available at: https://www.ncbi.nlm.nih.gov/pubmed/38416491.

30. Sheehan LA, Mehta AM, Sawan S, et al. Preserving fertility in pseudomyxoma peritonei, a novel approach. Pleura Peritoneum 2017;2:33–36. Available at: https://www.ncbi.nlm.nih.gov/pubmed/30911630.

31. Hanna N, Hanna AN, Hanna DN. AJCC Cancer Staging System Version 9: Appendiceal Adenocarcinoma. Ann Surg Oncol 2024;31:2177–2180. Available at: https://www.ncbi.nlm.nih.gov/pubmed/38240900.

32. Washington MK, Nagtegaal ID. Tumours of the appendix. WHO Classification of Tumours. Digestive system tumours. Vol. 1 (ed 5th). Lyon (France): International Agency for Research on Cancer 2019.

Version 2.2026 © 2026 National Comprehensive Cancer Network© (NCCN©), All rights reserved. NCCN Guidelines® and this illustration may not be reproduced in any form without the express written permission of NCCN.

PLEASE NOTE that use of this NCCN Content is governed by the End-User License Agreement, and you MAY NOT distribute this Content or use it with any artificial intelligence model or tool.
Printed by Máximo López Chenlo on 5/4/2026 6:12:29 PM. Copyright © 2026 National Comprehensive Cancer Network, Inc. All Rights Reserved.

33. Basturk O, Yang Z, Tang LH, et al. The high-grade (WHO G3) pancreatic neuroendocrine tumor category is morphologically and biologically heterogenous and includes both well differentiated and poorly differentiated neoplasms. Am J Surg Pathol 2015;39:683–690. Available at: https://www.ncbi.nlm.nih.gov/pubmed/25723112.

34. Overman MJ, Kakar S, Carr NJ, et al. AJCC Cancer Staging System, Version 9 Appendix: American College of Surgeons (ACS); 2022.

35. Carr NJ, Bibeau F, Bradley RF, et al. The histopathological classification, diagnosis and differential diagnosis of mucinous appendiceal neoplasms, appendiceal adenocarcinomas and pseudomyxoma peritonei. Histopathology 2017;71:847–858. Available at: https://www.ncbi.nlm.nih.gov/pubmed/28746986.

36. Carr NJ, Cecil TD, Mohamed F, et al. A Consensus for Classification and Pathologic Reporting of Pseudomyxoma Peritonei and Associated Appendiceal Neoplasia: The Results of the Peritoneal Surface Oncology Group International (PSOGI) Modified Delphi Process. Am J Surg Pathol 2016;40:14–26. Available at: https://www.ncbi.nlm.nih.gov/pubmed/26492181.

37. Pai RK, Hartman DJ, Gonzalo DH, et al. Serrated lesions of the appendix frequently harbor KRAS mutations and not BRAF mutations indicating a distinctly different serrated neoplastic pathway in the appendix. Hum Pathol 2014;45:227–235. Available at: https://www.ncbi.nlm.nih.gov/pubmed/24439221.

38. Dartigues P, Kepenekian V, Illac-Vauquelin C, et al. Insights into the Clinical Prognosis of High-grade Appendiceal Mucinous Neoplasms. Am J Surg Pathol 2025;49:499–507. Available at: https://www.ncbi.nlm.nih.gov/pubmed/39975985.

39. Gonzalez RS, Carr NJ, Liao H, et al. High-Grade Appendiceal Mucinous Neoplasm: Clinicopathologic Findings in 35 Cases. Arch Pathol Lab Med 2022;146:1471–1478. Available at: https://www.ncbi.nlm.nih.gov/pubmed/35472721.

40. Valasek MA, Pai RK. An Update on the Diagnosis, Grading, and Staging of Appendiceal Mucinous Neoplasms. Adv Anat Pathol 2018;25:38–60. Available at: https://www.ncbi.nlm.nih.gov/pubmed/29016471.

41. Nishikawa G, Sekine S, Ogawa R, et al. Frequent GNAS mutations in low-grade appendiceal mucinous neoplasms. Br J Cancer 2013;108:951–958. Available at: https://www.ncbi.nlm.nih.gov/pubmed/23403822.

42. Singhi AD, Davison JM, Choudry HA, et al. GNAS is frequently mutated in both low-grade and high-grade disseminated appendiceal mucinous neoplasms but does not affect survival. Hum Pathol 2014;45:1737–1743. Available at: https://www.ncbi.nlm.nih.gov/pubmed/24925222.

43. Wald AI, Pingpank JF, Ongchin M, et al. Targeted Next-Generation Sequencing Improves the Prognostication of Patients with Disseminated Appendiceal Mucinous Neoplasms (Pseudomyxoma Peritonei). Ann Surg Oncol 2023;30:7517–7526. Available at: https://www.ncbi.nlm.nih.gov/pubmed/37314541.

44. Doll J, Maurus K, Kohler F, et al. Molecular Profiling of Low-Grade Appendiceal Mucinous Neoplasms (LAMN). Genes Chromosomes Cancer 2024;63:e23270. Available at: https://www.ncbi.nlm.nih.gov/pubmed/39400480.

45. Liao X, Vavinskaya V, Sun K, et al. Mutation profile of high-grade appendiceal mucinous neoplasm. Histopathology 2020;76:461–469. Available at: https://www.ncbi.nlm.nih.gov/pubmed/31491041.

46. Seldomridge AN, White MG, Scally C, et al. Clinicopathologic and Molecular Characteristics of High-Grade Appendiceal Mucinous Neoplasms. Ann Surg Oncol 2026;33:2376–2387. Available at: https://www.ncbi.nlm.nih.gov/pubmed/41225239.

47. Misdraji J, Burgart LJ, Lauwers GY. Defective mismatch repair in the pathogenesis of low-grade appendiceal mucinous neoplasms and adenocarcinomas. Mod Pathol 2004;17:1447–1454. Available at: https://www.ncbi.nlm.nih.gov/pubmed/15354187.

Version 2.2026 © 2026 National Comprehensive Cancer Network© (NCCN©), All rights reserved. NCCN Guidelines® and this illustration may not be reproduced in any form without the express written permission of NCCN.

PLEASE NOTE that use of this NCCN Content is governed by the End-User License Agreement, and you MAY NOT distribute this Content or use it with any artificial intelligence model or tool.
Printed by Máximo López Chenlo on 5/4/2026 6:12:29 PM. Copyright © 2026 National Comprehensive Cancer Network, Inc. All Rights Reserved.

48. Yantiss RK. Advances in Surgical Pathology: Colorectal Carcinoma and Tumors of the Vermiform Appendix (ed 1). Philadelphia: Lippincott Williams & Wilkins (LWW); 2013:301-312.

49. Misdraji J, Young RH. Primary epithelial neoplasms and other epithelial lesions of the appendix (excluding carcinoid tumors). Semin Diagn Pathol 2004;21:120–133. Available at: https://www.ncbi.nlm.nih.gov/pubmed/15807472.

50. Taggart MW, Galbincea J, Mansfield PF, et al. High-level microsatellite instability in appendiceal carcinomas. Am J Surg Pathol 2013;37:1192–1200. Available at: https://www.ncbi.nlm.nih.gov/pubmed/23648460.

51. Ang CS, Shen JP, Hardy-Abeloos CJ, et al. Genomic Landscape of Appendiceal Neoplasms. JCO Precis Oncol 2018;2. Available at: https://www.ncbi.nlm.nih.gov/pubmed/32913983.

52. Tokunaga R, Xiu J, Johnston C, et al. Molecular Profiling of Appendiceal Adenocarcinoma and Comparison with Right-sided and Left-sided Colorectal Cancer. Clin Cancer Res 2019;25:3096–3103. Available at: https://www.ncbi.nlm.nih.gov/pubmed/30692096.

53. Foote MB, Walch H, Chatila W, et al. Molecular Classification of Appendiceal Adenocarcinoma. J Clin Oncol 2023;41:1553–1564. Available at: https://www.ncbi.nlm.nih.gov/pubmed/36493333.

54. White MG, Zeineddine MA, Fallon EA, et al. The Landscape of ctDNA in Appendiceal Adenocarcinoma. Clin Cancer Res 2025;31:551–560. Available at: https://www.ncbi.nlm.nih.gov/pubmed/39679931.

55. Raghav K, Shen JP, Jacome AA, et al. Integrated clinico-molecular profiling of appendiceal adenocarcinoma reveals a unique grade-driven entity distinct from colorectal cancer. Br J Cancer 2020;123:1262–1270. Available at: https://www.ncbi.nlm.nih.gov/pubmed/32733093.

56. Chen I, Liu X, Kovar-Peltz S, et al. Clinicopathological spectrums and prognosis of primary appendiceal adenocarcinoma, goblet cell adenocarcinoma, and low-grade appendiceal mucinous neoplasms. Pathology 2023;55:375–382. Available at: https://www.ncbi.nlm.nih.gov/pubmed/36454563.

57. Wen KW, Grenert JP, Joseph NM, et al. Genomic profile of appendiceal goblet cell carcinoid is distinct compared to appendiceal neuroendocrine tumor and conventional adenocarcinoma. Hum Pathol 2018;77:166–174. Available at: https://www.ncbi.nlm.nih.gov/pubmed/29634977.

58. Johncilla M, Stachler M, Misdraji J, et al. Mutational landscape of goblet cell carcinoids and adenocarcinoma ex goblet cell carcinoids of the appendix is distinct from typical carcinoids and colorectal adenocarcinomas. Mod Pathol 2018;31:989–996. Available at: https://www.ncbi.nlm.nih.gov/pubmed/29422640.

59. Govaerts K, Lurvink RJ, De Hingh I, et al. Appendiceal tumours and pseudomyxoma peritonei: Literature review with PSOGI/EURACAN clinical practice guidelines for diagnosis and treatment. Eur J Surg Oncol 2021;47:11–35. Available at: https://www.ncbi.nlm.nih.gov/pubmed/32199769.

60. Davison JM, Choudry HA, Pingpank JF, et al. Clinicopathologic and molecular analysis of disseminated appendiceal mucinous neoplasms: identification of factors predicting survival and proposed criteria for a three-tiered assessment of tumor grade. Mod Pathol 2014;27:1521–1539. Available at: https://www.ncbi.nlm.nih.gov/pubmed/24633196.

61. Benzerdjeb N, Durieux E, Tantot J, et al. Prognostic impact of combined progression index based on peritoneal grading regression score and peritoneal cytology in peritoneal metastasis. Histopathology 2020;77:548–559. Available at: https://www.ncbi.nlm.nih.gov/pubmed/32060943.

62. Solass W, Sempoux C, Detlefsen S, et al. Peritoneal sampling and histological assessment of therapeutic response in peritoneal metastasis: proposal of the Peritoneal Regression Grading Score (PRGS). Pleura Peritoneum 2016;1:99–107. Available at: https://www.ncbi.nlm.nih.gov/pubmed/30911613.

Version 2.2026 © 2026 National Comprehensive Cancer Network© (NCCN©), All rights reserved. NCCN Guidelines® and this illustration may not be reproduced in any form without the express written permission of NCCN.

PLEASE NOTE that use of this NCCN Content is governed by the End-User License Agreement, and you MAY NOT distribute this Content or use it with any artificial intelligence model or tool.
Printed by Máximo López Chenlo on 5/4/2026 6:12:29 PM. Copyright © 2026 National Comprehensive Cancer Network, Inc. All Rights Reserved.

63. Shaker N, Davison J, Derby J, et al. TP53 Alterations Are an Independent Adverse Prognostic Indicator in Pseudomyxoma Peritonei of Appendiceal Origin Following Cytoreductive Surgery and Intraperitoneal Chemotherapy. Appl Immunohistochem Mol Morphol 2025;33:70–77. Available at: https://www.ncbi.nlm.nih.gov/pubmed/39812318.

64. Lange S, Lisiecki H, Kreutzfeldt S, et al. Precision oncology for advanced-stage adenocarcinoma of the appendix: comprehensive molecular characterisation identifies actionable lesions and potential predictive biomarkers. BMJ Open Gastroenterol 2025;12. Available at: https://www.ncbi.nlm.nih.gov/pubmed/40840958.

65. Pattalachinti VK, Haque E, Yousef M, et al. BRAF mutant appendiceal adenocarcinoma differs from colorectal cancer but responds to BRAF-targeted therapy. NPJ Precis Oncol 2025;9:38. Available at: https://www.ncbi.nlm.nih.gov/pubmed/39910160.

66. White M, Helmink B, Rivero-Hinojosa S, et al. The genomic landscape of appendiceal adenocarcinoma revealed by 855 whole exome sequences [abstract]. Annals of Oncology 2023;34:S185. Available at: https://doi.org/10.1016/j.annonc.2023.04.026.

67. Pinto Leite N, Pereira JM, Cunha R, et al. CT evaluation of appendicitis and its complications: imaging techniques and key diagnostic findings. AJR Am J Roentgenol 2005;185:406–417. Available at: https://www.ncbi.nlm.nih.gov/pubmed/16037513.

68. Appendix Imaging. In: StatPearls. Treasure Osland, FL: StatPearls Publishing; 2025. Available at: https://www.ncbi.nlm.nih.gov/books/NBK549903/. Accessed December 23, 2025.

69. Karande GY, Chua WM, Yiin RSZ, et al. Spectrum of computed tomography manifestations of appendiceal neoplasms: acute appendicitis and beyond. Singapore Med J 2019;60:173–182. Available at: https://www.ncbi.nlm.nih.gov/pubmed/31069398.

70. Rohani P, Scotti SD, Shen P, et al. Use of FDG-PET imaging for patients with disseminated cancer of the appendix. Am Surg 2010;76:1338–1344. Available at: https://www.ncbi.nlm.nih.gov/pubmed/21265346.

71. Low RN, Barone RM, Lucero J. Comparison of MRI and CT for predicting the Peritoneal Cancer Index (PCI) preoperatively in patients being considered for cytoreductive surgical procedures. Ann Surg Oncol 2015;22:1708–1715. Available at: https://www.ncbi.nlm.nih.gov/pubmed/25201499.

72. Di Leo A, Corvasce A, Weindelmayer J, et al. Cytoreductive surgery (CRS) and hyperthermic intraperitoneal chemotherapy (HIPEC) in pseudomyxoma peritonei of appendiceal origin: result of a single centre study. Updates Surg 2020;72:1207–1212. Available at: https://www.ncbi.nlm.nih.gov/pubmed/32410159.

73. Torkzad MR, Casta N, Bergman A, et al. Comparison between MRI and CT in prediction of peritoneal carcinomatosis index (PCI) in patients undergoing cytoreductive surgery in relation to the experience of the radiologist. J Surg Oncol 2015;111:746–751. Available at: https://www.ncbi.nlm.nih.gov/pubmed/25580825.

74. Low RN, Barone RM, Gurney JM, Muller WD. Mucinous appendiceal neoplasms: preoperative MR staging and classification compared with surgical and histopathologic findings. AJR Am J Roentgenol 2008;190:656–665. Available at: https://www.ncbi.nlm.nih.gov/pubmed/18287436.

75. Glasgow SC, Gaertner W, Stewart D, et al. The American Society of Colon and Rectal Surgeons, Clinical Practice Guidelines for the Management of Appendiceal Neoplasms. Dis Colon Rectum 2019;62:1425–1438. Available at: https://www.ncbi.nlm.nih.gov/pubmed/31725580.

76. Aguirre N, Chung SK, Foote MB, et al. Predictors of Recurrence in Nonmetastatic Appendiceal Epithelial Cancers: An Updated Single-Center Experience Over 25 Years. Ann Surg Oncol 2025;32:695–702. Available at: https://www.ncbi.nlm.nih.gov/pubmed/39604747.

Version 2.2026 © 2026 National Comprehensive Cancer Network© (NCCN©), All rights reserved. NCCN Guidelines® and this illustration may not be reproduced in any form without the express written permission of NCCN.

PLEASE NOTE that use of this NCCN Content is governed by the End-User License Agreement, and you MAY NOT distribute this Content or use it with any artificial intelligence model or tool.
Printed by Máximo López Chenlo on 5/4/2026 6:12:29 PM. Copyright © 2026 National Comprehensive Cancer Network, Inc. All Rights Reserved.

77. Tan GHC, Shamji T, Mehta A, et al. Diagnostic and therapeutic laparoscopy in assessment and management of patients with appendiceal neoplasms. Int J Hyperthermia 2018;34:336–340. Available at: https://www.ncbi.nlm.nih.gov/pubmed/28605985.

78. Tam AL, Lim HJ, Wistuba, II, et al. Image-Guided Biopsy in the Era of Personalized Cancer Care: Proceedings from the Society of Interventional Radiology Research Consensus Panel. J Vasc Interv Radiol 2016;27:8–19. Available at: https://www.ncbi.nlm.nih.gov/pubmed/26626860.

79. Cornman-Homonoff J, Madoff DC. Image-guided biopsy of mesenteric, omental, and peritoneal disease. Digestive Disease Interventions 2018;2:106–115. Available at: https://www.thieme-connect.com/products/ejournals/pdf/10.1055/s-0038-1660499.pdf.

80. Bolmers MDM, de Jonge J, van Rossem CC, et al. Appendicular neoplasms and consequences in patients undergoing surgery for suspected acute appendicitis. Int J Colorectal Dis 2020;35:2065–2071. Available at: https://www.ncbi.nlm.nih.gov/pubmed/32638091.

81. Gao J, Chu Z, Chen J, et al. Retrospective analysis of 9 cases of appendiceal mucocele in 3,071 cases of appendicitis. Biomed Rep 2022;17:55. Available at: https://www.ncbi.nlm.nih.gov/pubmed/35719842.

82. Le Donne ME, Herman M. Appendiceal Mucocele Presenting as a Cecal Bulge on Surveillance Colonoscopy. Cureus 2024;16:e69283. Available at: https://www.ncbi.nlm.nih.gov/pubmed/39398782.

83. Nunez-Rocha RE, Giron F, Rodriguez L, et al. Incidence of appendiceal neoplasms in appendectomy patients. BMC Surg 2023;23:287. Available at: https://www.ncbi.nlm.nih.gov/pubmed/37735406.

84. Tchana-Sato V, Detry O, Polus M, et al. Carcinoid tumor of the appendix: a consecutive series from 1237 appendectomies. World J Gastroenterol 2006;12:6699–6701. Available at: https://www.ncbi.nlm.nih.gov/pubmed/17075987.

85. Foroutani L, Wang JJ, Kiran S, et al. True Incidence of Appendiceal Neoplasms in Patients Presenting with Complicated Appendicitis: A Call for a Revised Management Algorithm. Ann Surg Oncol 2026. Available at: https://www.ncbi.nlm.nih.gov/pubmed/41524877.

86. Young S, Sueda SK, Hotta M, et al. Surgical management of appendiceal mucinous neoplasm: Is appendectomy sufficient? J Surg Oncol 2020;122:1173–1178. Available at: https://www.ncbi.nlm.nih.gov/pubmed/32638405.

87. Biondi A, Di Stefano C, Ferrara F, et al. Laparoscopic versus open appendectomy: a retrospective cohort study assessing outcomes and cost-effectiveness. World J Emerg Surg 2016;11:44. Available at: https://www.ncbi.nlm.nih.gov/pubmed/27582784.

88. Jaschinski T, Mosch CG, Eikermann M, et al. Laparoscopic versus open surgery for suspected appendicitis. Cochrane Database Syst Rev 2018;11:CD001546. Available at: https://www.ncbi.nlm.nih.gov/pubmed/30484855.

89. Nazir A, Farooqi SA, Chaudhary NA, et al. Comparison of Open Appendectomy and Laparoscopic Appendectomy in Perforated Appendicitis. Cureus 2019;11:e5105. Available at: https://www.ncbi.nlm.nih.gov/pubmed/31523536.

90. Inoue A, Murata K, Komori T, et al. Open versus laparoscopic surgery for primary appendiceal tumors: a large multicenter retrospective propensity score-matched cohort study in Japan. Surg Endosc 2021;35:5515–5523. Available at: https://www.ncbi.nlm.nih.gov/pubmed/32995963.

91. Quirante FP, Montorfano LM, Serrot F, et al. The case of the missing appendix: a case report of appendiceal intussusception at the site of colonic mullerianosis. Gastroenterol Rep (Oxf) 2017;5:309–312. Available at: https://www.ncbi.nlm.nih.gov/pubmed/26383877.

92. Harris BF, Collins CN, Gerard JD. A standardized surgical approach to appendiceal orifice tumors: a case report. J Surg Case Rep

Version 2.2026 © 2026 National Comprehensive Cancer Network© (NCCN©), All rights reserved. NCCN Guidelines® and this illustration may not be reproduced in any form without the express written permission of NCCN.

PLEASE NOTE that use of this NCCN Content is governed by the End-User License Agreement, and you MAY NOT distribute this Content or use it with any artificial intelligence model or tool.
Printed by Máximo López Chenlo on 5/4/2026 6:12:29 PM. Copyright © 2026 National Comprehensive Cancer Network, Inc. All Rights Reserved.

2025;2025:rjaf259. Available at: https://www.ncbi.nlm.nih.gov/pubmed/40313371.

93. Rossi A, Maloney Patel N. Appendiceal neoplasms-A practical guide. J Surg Oncol 2023;127:1300–1305. Available at: https://www.ncbi.nlm.nih.gov/pubmed/37222692.

94. Ciarrocchi A, Pietroletti R, Carlei F, Amicucci G. Clinical Significance of Metastatic Lymph Nodes in the Gut of Patients with Pure and Mixed Primary Appendiceal Carcinoids. Dis Colon Rectum 2016;59:508–512. Available at: https://www.ncbi.nlm.nih.gov/pubmed/27145307.

95. Ito H, Osteen RT, Bleday R, et al. Appendiceal adenocarcinoma: long-term outcomes after surgical therapy. Dis Colon Rectum 2004;47:474–480. Available at: https://www.ncbi.nlm.nih.gov/pubmed/14978617.

96. AlMasri SS, Hammad AY, Singhi AD, et al. Appendectomy Is Oncologically Equivalent to Right Hemicolectomy for Well-Differentiated T1 Appendiceal Adenocarcinoma. Dis Colon Rectum 2023;66:67–74. Available at: https://www.ncbi.nlm.nih.gov/pubmed/34508015.

97. Marks VA, Kerekes D, Butensky S, et al. Role of colectomy in the management of appendiceal tumors: a retrospective cohort study. BMC Gastroenterol 2023;23:398. Available at: https://www.ncbi.nlm.nih.gov/pubmed/37978348.

98. Zhang Q, Xia G, Mo A, et al. Prognostic analysis of appendectomy versus right hemicolectomy for T1 appendiceal adenocarcinoma: a multicenter retrospective analysis. Sci Rep 2024;14:21503. Available at: https://www.ncbi.nlm.nih.gov/pubmed/39277639.

99. Mehrvarz Sarshekeh A, Advani S, Halperin DM, et al. Regional lymph node involvement and outcomes in appendiceal neuroendocrine tumors: a SEER database analysis. Oncotarget 2017;8:99541–99551. Available at: https://www.ncbi.nlm.nih.gov/pubmed/29245922.

100. Gonzalez-Moreno S, Sugarbaker PH. Right hemicolectomy does not confer a survival advantage in patients with mucinous carcinoma of the appendix and peritoneal seeding. Br J Surg 2004;91:304–311. Available at: https://www.ncbi.nlm.nih.gov/pubmed/14991630.

101. College of American Pathologists. Protocol for the Examination of Specimens From Patients With Carcinoma of the Appendix. College of American Pathologists; 2022. Available at: https://documents.cap.org/protocols/Appendix_5.1.0.0.REL_CAPCP.pdf?_gl=1*1rr8ttm*_ga*NzEzMTk5MzQxLjE3NjM3NDExMTc.*_ga_97ZFJSQQ0X*czE3NjM3NDExMTYkbzEkZzEkdDE3NjM3NDExNTgkajE4JGwwJGgw. Accessed November 21, 2025.

102. Fleischmann I, Warschkow R, Beutner U, et al. Improved survival after retrieval of 12 or more regional lymph nodes in appendiceal cancer. Eur J Surg Oncol 2017;43:1876–1885. Available at: https://www.ncbi.nlm.nih.gov/pubmed/28734542.

103. Winicki NM, Florissi IS, Radomski SN, et al. Minimum number of lymph nodes to maximize survival in non-metastatic appendiceal adenocarcinoma. Surgical Oncology Insight 2024;1:100077. Available at: https://www.sciencedirect.com/science/article/pii/S2950247024000860.

104. Guaglio M, Sinukumar S, Kusamura S, et al. Clinical Surveillance After Macroscopically Complete Surgery for Low-Grade Appendiceal Mucinous Neoplasms (LAMN) with or Without Limited Peritoneal Spread: Long-Term Results in a Prospective Series. Ann Surg Oncol 2018;25:878–884. Available at: https://www.ncbi.nlm.nih.gov/pubmed/29270877.

105. Lohani KR, Sonani H, Buckarma E, et al. Risk stratification of surveillance for low-grade appendiceal mucinous neoplasms. J Gastrointest Surg 2024;28:1906–1911. Available at: https://www.ncbi.nlm.nih.gov/pubmed/39209560.

106. Wang B, Ma R, Shi G, et al. Hyperthermic intraperitoneal chemotherapy in patients with incomplete cytoreduction for appendiceal pseudomyxoma peritonei: a 10-year treatment experience in China. Orphanet J Rare Dis 2024;19:8. Available at: https://www.ncbi.nlm.nih.gov/pubmed/38178189.

Version 2.2026 © 2026 National Comprehensive Cancer Network© (NCCN©), All rights reserved. NCCN Guidelines® and this illustration may not be reproduced in any form without the express written permission of NCCN.

PLEASE NOTE that use of this NCCN Content is governed by the End-User License Agreement, and you MAY NOT distribute this Content or use it with any artificial intelligence model or tool.
Printed by Máximo López Chenlo on 5/4/2026 6:12:29 PM. Copyright © 2026 National Comprehensive Cancer Network, Inc. All Rights Reserved.

107. Harper MM, Kim J, Pandalai PK. Current Trends in Cytoreductive Surgery (CRS) and Hyperthermic Intraperitoneal Chemotherapy (HIPEC) for Peritoneal Disease from Appendiceal and Colorectal Malignancies. J Clin Med 2022;11. Available at: https://www.ncbi.nlm.nih.gov/pubmed/35628966.

108. Valle SJ, Alzahrani NA, Liauw W, et al. Hyperthermic Intraperitoneal Chemotherapy (HIPEC) Methodology, Drugs and Bidirectional Chemotherapy. Indian J Surg Oncol 2016;7:152–159. Available at: https://www.ncbi.nlm.nih.gov/pubmed/27065705.

109. Auer RC, Sivajohanathan D, Biagi J, et al. Indications for hyperthermic intraperitoneal chemotherapy with cytoreductive surgery: a systematic review. Eur J Cancer 2020;127:76–95. Available at: https://www.ncbi.nlm.nih.gov/pubmed/31986452.

110. Byrne RM, Gilbert EW, Dewey EN, et al. Who Undergoes Cytoreductive Surgery and Perioperative Intraperitoneal Chemotherapy for Appendiceal Cancer? An Analysis of the National Cancer Database. J Surg Res 2019;238:198–206. Available at: https://www.ncbi.nlm.nih.gov/pubmed/30772678.

111. Sugarbaker PH, Chang D. Secondary cytoreductive surgery for low-grade appendiceal mucinous neoplasms. J Surg Oncol 2022;126:1451–1461. Available at: https://www.ncbi.nlm.nih.gov/pubmed/35975822.

112. Sugarbaker PH, Chang D, Liang J. Pathogenesis of histologic variations of appendiceal mucinous neoplasms. Eur J Surg Oncol 2023;49:895–901. Available at: https://www.ncbi.nlm.nih.gov/pubmed/36863914.

113. Glehen O, Gilly FN, Boutitie F, et al. Toward curative treatment of peritoneal carcinomatosis from nonovarian origin by cytoreductive surgery combined with perioperative intraperitoneal chemotherapy: a multi-institutional study of 1,290 patients. Cancer 2010;116:5608–5618. Available at: https://www.ncbi.nlm.nih.gov/pubmed/20737573.

114. Garach NR, Kusamura S, Guaglio M, et al. Comparative study of mucinous and non-mucinous appendiceal neoplasms with peritoneal dissemination treated by cyoreductive surgery and hyperthermic intraperitoneal chemotherapy (HIPEC). Eur J Surg Oncol 2021;47:1132–1139. Available at: https://www.ncbi.nlm.nih.gov/pubmed/33280949.

115. Erstad DJ, Robinson KA, Beaty K, et al. Prognostic significance of acellular mucin in patients undergoing cytoreductive surgery and hyperthermic intraperitoneal chemotherapy (CRS/HIPEC) for appendiceal neoplasms. Langenbecks Arch Surg 2023;408:110. Available at: https://www.ncbi.nlm.nih.gov/pubmed/36853519.

116. Chua TC, Al-Alem I, Saxena A, et al. Surgical cytoreduction and survival in appendiceal cancer peritoneal carcinomatosis: an evaluation of 46 consecutive patients. Ann Surg Oncol 2011;18:1540–1546. Available at: https://www.ncbi.nlm.nih.gov/pubmed/21491165.

117. Munoz-Zuluaga CA, King MC, Ledakis P, et al. Systemic chemotherapy before cytoreductive surgery and hyperthermic intraperitoneal chemotherapy (CRS/HIPEC) in patients with high-grade mucinous carcinoma peritonei of appendiceal origin. Eur J Surg Oncol 2019;45:1598–1606. Available at: https://www.ncbi.nlm.nih.gov/pubmed/31109821.

118. Austin F, Mavanur A, Sathaiah M, et al. Aggressive management of peritoneal carcinomatosis from mucinous appendiceal neoplasms. Ann Surg Oncol 2012;19:1386–1393. Available at: https://www.ncbi.nlm.nih.gov/pubmed/22302270.

119. Rodriguez-Ortiz L, Arjona-Sanchez A, Ibanez-Rubio M, et al. Laparoscopic cytoreductive surgery and HIPEC: a comparative matched analysis. Surg Endosc 2021;35:1778–1785. Available at: https://www.ncbi.nlm.nih.gov/pubmed/32328823.

120. Rao A, Mui J, Barat S, et al. Peritoneal Spread of Low-grade Appendiceal Tumours - 2 Days of Early Postoperative Intra-peritoneal Chemotherapy Are Enough. Anticancer Res 2021;41:5569–5575. Available at: https://www.ncbi.nlm.nih.gov/pubmed/34732427.

121. Grotz TE, Overman MJ, Eng C, et al. Cytoreductive Surgery and Hyperthermic Intraperitoneal Chemotherapy for Moderately and Poorly

Version 2.2026 © 2026 National Comprehensive Cancer Network© (NCCN©), All rights reserved. NCCN Guidelines® and this illustration may not be reproduced in any form without the express written permission of NCCN.

PLEASE NOTE that use of this NCCN Content is governed by the End-User License Agreement, and you MAY NOT distribute this Content or use it with any artificial intelligence model or tool.
Printed by Máximo López Chenlo on 5/4/2026 6:12:29 PM. Copyright © 2026 National Comprehensive Cancer Network, Inc. All Rights Reserved.

Differentiated Appendiceal Adenocarcinoma: Survival Outcomes and Patient Selection. Ann Surg Oncol 2017;24:2646–2654. Available at: https://www.ncbi.nlm.nih.gov/pubmed/28695394.

122. Marmor RA, Kelly KJ, Lowy AM, Baumgartner JM. Laparoscopy is Safe and Accurate to Evaluate Peritoneal Surface Metastasis Prior to Cytoreductive Surgery. Ann Surg Oncol 2016;23:1461–1467. Available at: https://www.ncbi.nlm.nih.gov/pubmed/26542584.

123. Szadkowska MA, Palucki J, Cieszanowski A. Diagnosis and treatment of peritoneal carcinomatosis - a comprehensive overview. Pol J Radiol 2023;88:e89–e97. Available at: https://www.ncbi.nlm.nih.gov/pubmed/36910885.

124. Harmon RL, Sugarbaker PH. Prognostic indicators in peritoneal carcinomatosis from gastrointestinal cancer. Int Semin Surg Oncol 2005;2:3. Available at: https://www.ncbi.nlm.nih.gov/pubmed/15701175.

125. Dohan A, Hoeffel C, Soyer P, et al. Evaluation of the peritoneal carcinomatosis index with CT and MRI. Br J Surg 2017;104:1244–1249. Available at: https://www.ncbi.nlm.nih.gov/pubmed/28376270.

126. Mohkam K, Passot G, Cotte E, et al. Resectability of Peritoneal Carcinomatosis: Learnings from a Prospective Cohort of 533 Consecutive Patients Selected for Cytoreductive Surgery. Ann Surg Oncol 2016;23:1261–1270. Available at: https://www.ncbi.nlm.nih.gov/pubmed/26628435.

127. Jacquet P, Sugarbaker PH. Clinical research methodologies in diagnosis and staging of patients with peritoneal carcinomatosis. Cancer Treat Res 1996;82:359–374. Available at: https://www.ncbi.nlm.nih.gov/pubmed/8849962.

128. de Boer NL, Brandt-Kerkhof ARM, Madsen EVE, et al. The Accuracy of the Surgical Peritoneal Cancer Index in Patients with Peritoneal Metastases of Colorectal Cancer. Dig Surg 2021;38:205–211. Available at: https://www.ncbi.nlm.nih.gov/pubmed/33657551.

129. Votanopoulos KI, Bartlett D, Moran B, et al. PCI is Not Predictive of Survival After Complete CRS/HIPEC in Peritoneal Dissemination from High-Grade Appendiceal Primaries. Ann Surg Oncol 2018;25:674–678. Available at: https://www.ncbi.nlm.nih.gov/pubmed/29288288.

130. Mehta SS, Bhatt A, Glehen O. Cytoreductive Surgery and Peritonectomy Procedures. Indian J Surg Oncol 2016;7:139–151. Available at: https://www.ncbi.nlm.nih.gov/pubmed/27065704.

131. Karpes JB, Lansom JD, Alshahrani M, et al. Repeat cytoreductive surgery with or without intraperitoneal chemotherapy for recurrent epithelial appendiceal neoplasms. BJS Open 2020;4:478–485. Available at: https://www.ncbi.nlm.nih.gov/pubmed/32020757.

132. Valenzuela CD, Mangieri CW, Garland-Kledzik M, et al. Timing of Repeat Cytoreductive Surgery with Hyperthermic Intraperitoneal Chemotherapy for Recurrent Low-Grade Appendiceal Mucinous Neoplasms. Ann Surg Oncol 2022;29:3422–3431. Available at: https://www.ncbi.nlm.nih.gov/pubmed/35254575.

133. Esquivel J, Sugarbaker PH. Second-look surgery in patients with peritoneal dissemination from appendiceal malignancy: analysis of prognostic factors in 98 patients. Ann Surg 2001;234:198–205. Available at: https://www.ncbi.nlm.nih.gov/pubmed/11505065.

134. Votanopoulos KI, Ihemelandu C, Shen P, et al. Outcomes of repeat cytoreductive surgery with hyperthermic intraperitoneal chemotherapy for the treatment of peritoneal surface malignancy. J Am Coll Surg 2012;215:412–417. Available at: https://www.ncbi.nlm.nih.gov/pubmed/22634117.

135. Bhutiani N, Grotz TE, Concors SJ, et al. Repeat Cytoreduction and Hyperthermic Intraperitoneal Chemotherapy for Recurrent Mucinous Appendiceal Adenocarcinoma: A Viable Treatment Strategy with Demonstrable Benefit. Ann Surg Oncol 2024;31:614–621. Available at: https://www.ncbi.nlm.nih.gov/pubmed/37872456.

136. Zambrano-Vera K, Sardi A, Munoz-Zuluaga C, et al. Outcomes in Peritoneal Carcinomatosis from Appendiceal Goblet Cell Carcinoma

Version 2.2026 © 2026 National Comprehensive Cancer Network© (NCCN©), All rights reserved. NCCN Guidelines® and this illustration may not be reproduced in any form without the express written permission of NCCN.

PLEASE NOTE that use of this NCCN Content is governed by the End-User License Agreement, and you MAY NOT distribute this Content or use it with any artificial intelligence model or tool.
Printed by Máximo López Chenlo on 5/4/2026 6:12:29 PM. Copyright © 2026 National Comprehensive Cancer Network, Inc. All Rights Reserved.

Treated with Cytoreductive Surgery and Hyperthermic Intraperitoneal Chemotherapy (CRS/HIPEC). Ann Surg Oncol 2020;27:179–187. Available at: https://www.ncbi.nlm.nih.gov/pubmed/31646450.

137. Graves A, Sadjadi J, Kosich M, et al. Decision Regret in Patients with Appendiceal Cancer Undergoing Cytoreductive Surgery and Hyperthermic Intraperitoneal Chemotherapy. Ann Surg Oncol 2024;31:7978–7986. Available at: https://www.ncbi.nlm.nih.gov/pubmed/39192009.

138. Goodman MD, McPartland S, Detelich D, Saif MW. Chemotherapy for intraperitoneal use: a review of hyperthermic intraperitoneal chemotherapy and early post-operative intraperitoneal chemotherapy. J Gastrointest Oncol 2016;7:45–57. Available at: https://www.ncbi.nlm.nih.gov/pubmed/26941983.

139. Levine EA, Votanopoulos KI, Shen P, et al. A Multicenter Randomized Trial to Evaluate Hematologic Toxicities after Hyperthermic Intraperitoneal Chemotherapy with Oxaliplatin or Mitomycin in Patients with Appendiceal Tumors. J Am Coll Surg 2018;226:434–443. Available at: https://www.ncbi.nlm.nih.gov/pubmed/29331663.

140. Levine EA, Cos H, Votanopoulos KI, et al. Ten-Year Outcome of a Randomized Trial: Cytoreduction and HIPEC with Mitomycin C Versus Oxaliplatin for Appendiceal Neoplasm with Peritoneal Dissemination. Ann Surg Oncol 2025;32:679–686. Available at: https://www.ncbi.nlm.nih.gov/pubmed/39531120.

141. Cioppa T, Vaira M, Bing C, et al. Cytoreduction and hyperthermic intraperitoneal chemotherapy in the treatment of peritoneal carcinomatosis from pseudomyxoma peritonei. World J Gastroenterol 2008;14:6817–6823. Available at: https://www.ncbi.nlm.nih.gov/pubmed/19058307.

142. Deraco M, Baratti D, Inglese MG, et al. Peritonectomy and intraperitoneal hyperthermic perfusion (IPHP): a strategy that has confirmed its efficacy in patients with pseudomyxoma peritonei. Ann Surg Oncol 2004;11:393–398. Available at: https://www.ncbi.nlm.nih.gov/pubmed/15070599.

143. Elias D, Gilly F, Quenet F, et al. Pseudomyxoma peritonei: a French multicentric study of 301 patients treated with cytoreductive surgery and intraperitoneal chemotherapy. Eur J Surg Oncol 2010;36:456–462. Available at: https://www.ncbi.nlm.nih.gov/pubmed/20227231.

144. Loungnarath R, Causeret S, Bossard N, et al. Cytoreductive surgery with intraperitoneal chemohyperthermia for the treatment of pseudomyxoma peritonei: a prospective study. Dis Colon Rectum 2005;48:1372–1379. Available at: https://www.ncbi.nlm.nih.gov/pubmed/15909071.

145. Sugarbaker PH, Chang D. Results of treatment of 385 patients with peritoneal surface spread of appendiceal malignancy. Ann Surg Oncol 1999;6:727–731. Available at: https://www.ncbi.nlm.nih.gov/pubmed/10622499.

146. Stewart JHt, Shen P, Russell GB, et al. Appendiceal neoplasms with peritoneal dissemination: outcomes after cytoreductive surgery and intraperitoneal hyperthermic chemotherapy. Ann Surg Oncol 2006;13:624–634. Available at: https://www.ncbi.nlm.nih.gov/pubmed/16538401.

147. Kusamura S, Barretta F, Yonemura Y, et al. The Role of Hyperthermic Intraperitoneal Chemotherapy in Pseudomyxoma Peritonei After Cytoreductive Surgery. JAMA Surg 2021;156:e206363. Available at: https://www.ncbi.nlm.nih.gov/pubmed/33502455.

148. Karimi M, Shirsalimi N, Sedighi E. Challenges following CRS and HIPEC surgery in cancer patients with peritoneal metastasis: a comprehensive review of clinical outcomes. Front Surg 2024;11:1498529. Available at: https://www.ncbi.nlm.nih.gov/pubmed/39687325.

149. Desolneux G, Maziere C, Vara J, et al. Cytoreductive surgery of colorectal peritoneal metastases: outcomes after complete cytoreductive surgery and systemic chemotherapy only. PLoS One 2015;10:e0122816. Available at: https://www.ncbi.nlm.nih.gov/pubmed/25825874.

150. Smibert OC, Slavin MA, Teh B, et al. Epidemiology and risks for infection following cytoreductive surgery and hyperthermic intra-peritoneal

Version 2.2026 © 2026 National Comprehensive Cancer Network© (NCCN©), All rights reserved. NCCN Guidelines® and this illustration may not be reproduced in any form without the express written permission of NCCN.

PLEASE NOTE that use of this NCCN Content is governed by the End-User License Agreement, and you MAY NOT distribute this Content or use it with any artificial intelligence model or tool.
Printed by Máximo López Chenlo on 5/4/2026 6:12:29 PM. Copyright © 2026 National Comprehensive Cancer Network, Inc. All Rights Reserved.

chemotherapy. Support Care Cancer 2020;28:2745–2752. Available at: https://www.ncbi.nlm.nih.gov/pubmed/31712951.

151. Ashraf Ganjouei A, Wang J, Yi C, et al. Predicting Severe Postoperative Complications after CRS-HIPEC: An Externally Validated Machine-Learning Tool. World J Surg 2025;49:1546–1554. Available at: https://www.ncbi.nlm.nih.gov/pubmed/40295427.

152. Winicki NM, Radomski SN, Ciftci Y, et al. Predicting Postoperative Infection After Cytoreductive Surgery and Hyperthermic Intraperitoneal Chemotherapy with Splenectomy. Ann Surg Oncol 2025;32:2903–2911. Available at: https://www.ncbi.nlm.nih.gov/pubmed/39841336.

153. Adam MA, Zhou H, Byrd J, et al. Predicting Severe Complications from Cytoreductive Surgery with Hyperthermic Intraperitoneal Chemotherapy: A Data-Driven, Machine Learning Approach to Augment Clinical Judgment. Ann Surg Oncol 2023;30:5433–5442. Available at: https://www.ncbi.nlm.nih.gov/pubmed/37266808.

154. Strach MC, Sutherland S, Horvath LG, Mahon K. The role of chemotherapy in the treatment of advanced appendiceal cancers: summary of the literature and future directions. Ther Adv Med Oncol 2022;14:17588359221112478. Available at: https://www.ncbi.nlm.nih.gov/pubmed/35898968.

155. Egbert L, Norain A, Stucky CC, et al. Cancer embryonic antigen (CEA) levels in patients with appendiceal adenocarcinoma predict response to neo-adjuvant chemotherapy and overall survival. J Surg Oncol 2023;127:688–698. Available at: https://www.ncbi.nlm.nih.gov/pubmed/36519637.

156. Turner KM, Hanna NN, Zhu Y, et al. Assessment of neoadjuvant chemotherapy on operative parameters and outcome in patients with peritoneal dissemination from high-grade appendiceal cancer. Ann Surg Oncol 2013;20:1068–1073. Available at: https://www.ncbi.nlm.nih.gov/pubmed/23456383.

157. Bijelic L, Kumar AS, Stuart OA, Sugarbaker PH. Systemic Chemotherapy prior to Cytoreductive Surgery and HIPEC for Carcinomatosis from Appendix Cancer: Impact on Perioperative Outcomes and Short-Term Survival. Gastroenterol Res Pract 2012;2012:163284. Available at: https://www.ncbi.nlm.nih.gov/pubmed/22899903.

158. Milovanov V, Sardi A, Ledakis P, et al. Systemic chemotherapy (SC) before cytoreductive surgery and hyperthermic intraperitoneal chemotherapy (CRS/HIPEC) in patients with peritoneal mucinous carcinomatosis of appendiceal origin (PMCA). Eur J Surg Oncol 2015;41:707–712. Available at: https://www.ncbi.nlm.nih.gov/pubmed/25633641.

159. Hanna DN, Macfie R, Ghani MO, et al. Association of Systemic Chemotherapy Approaches With Outcomes in Appendiceal Peritoneal Metastases. J Surg Res 2023;284:94–100. Available at: https://www.ncbi.nlm.nih.gov/pubmed/36563453.

160. Morgan RB, Yan A, Dhiman A, et al. Survival in Total Preoperative vs. Perioperative Chemotherapy for Patients with Metastatic High-Grade Appendiceal Adenocarcinoma Undergoing CRS/HIPEC. J Gastrointest Surg 2022;26:2591–2594. Available at: https://www.ncbi.nlm.nih.gov/pubmed/35879590.

161. Glockzin G, Zeman F, Croner RS, et al. Perioperative Systemic Chemotherapy, Cytoreductive Surgery, and Hyperthermic Intraperitoneal Chemotherapy in Patients With Colorectal Peritoneal Metastasis: Results of the Prospective Multicenter Phase 2 COMBATAC Trial. Clin Colorectal Cancer 2018;17:285–296. Available at: https://www.ncbi.nlm.nih.gov/pubmed/30131226.

162. Chen JC, Beal EW, Hays J, et al. Outcomes of neoadjuvant chemotherapy before CRS-HIPEC for patients with appendiceal cancer. J Surg Oncol 2020;122:388–398. Available at: https://www.ncbi.nlm.nih.gov/pubmed/32383206.

163. Sugarbaker PH, Bijelic L, Chang D, Yoo D. Neoadjuvant FOLFOX chemotherapy in 34 consecutive patients with mucinous peritoneal carcinomatosis of appendiceal origin. J Surg Oncol 2010;102:576–581. Available at: https://www.ncbi.nlm.nih.gov/pubmed/20737420.

Version 2.2026 © 2026 National Comprehensive Cancer Network© (NCCN©), All rights reserved. NCCN Guidelines® and this illustration may not be reproduced in any form without the express written permission of NCCN.

PLEASE NOTE that use of this NCCN Content is governed by the End-User License Agreement, and you MAY NOT distribute this Content or use it with any artificial intelligence model or tool.
Printed by Máximo López Chenlo on 5/4/2026 6:12:29 PM. Copyright © 2026 National Comprehensive Cancer Network, Inc. All Rights Reserved.

164. Cummins KA, Russell GB, Votanopoulos KI, et al. Peritoneal dissemination from high-grade appendiceal cancer treated with cytoreductive surgery (CRS) and hyperthermic intraperitoneal chemotherapy (HIPEC). J Gastrointest Oncol 2016;7:3–9. Available at: https://www.ncbi.nlm.nih.gov/pubmed/26941979.

165. Votanopoulos KI, Russell G, Randle RW, et al. Peritoneal surface disease (PSD) from appendiceal cancer treated with cytoreductive surgery (CRS) and hyperthermic intraperitoneal chemotherapy (HIPEC): overview of 481 cases. Ann Surg Oncol 2015;22:1274–1279. Available at: https://www.ncbi.nlm.nih.gov/pubmed/25319583.

166. Flood MP, Roberts G, Mitchell C, et al. Impact of neoadjuvant systemic chemotherapy followed by cytoreductive surgery and hyperthermic intraperitoneal chemotherapy for appendiceal adenocarcinoma. Asia Pac J Clin Oncol 2024;20:32–40. Available at: https://www.ncbi.nlm.nih.gov/pubmed/36880398.

167. Ruff SM, Kasumova G, Palavalli M, et al. Long term outcomes associated with the use of perioperative systemic chemotherapy on low grade appendiceal mucinous neoplasms with pseudomyxoma peritonei treated with cytoreductive surgery and hyperthermic intraperitoneal chemotherapy. Front Oncol 2024;14:1456920. Available at: https://www.ncbi.nlm.nih.gov/pubmed/39850813.

168. Mangieri CW, Moaven O, Valenzuela CD, et al. Utility of Neoadjuvant Chemotherapy for Peritoneal Carcinomatosis Secondary to High-Grade Appendiceal Neoplasms for Patients Undergoing Cytoreductive Surgery with Hyperthermic Intraperitoneal Chemotherapy. Ann Surg Oncol 2022;29:2641–2648. Available at: https://www.ncbi.nlm.nih.gov/pubmed/35022900.

169. Kolla BC, Petersen A, Chengappa M, et al. Impact of adjuvant chemotherapy on outcomes in appendiceal cancer. Cancer Med 2020;9:3400–3406. Available at: https://www.ncbi.nlm.nih.gov/pubmed/32189461.

170. Wu HT, Yang XJ, Huang CQ, et al. Cytoreductive surgery plus hyperthermic intraperitoneal chemotherapy with lobaplatin and docetaxel improves survival for patients with peritoneal carcinomatosis from abdominal and pelvic malignancies. World J Surg Oncol 2016;14:246. Available at: https://www.ncbi.nlm.nih.gov/pubmed/27633880.

171. Tsang ES, McConnell YJ, Schaeffer DF, et al. Outcomes of Surgical and Chemotherapeutic Treatments of Goblet Cell Carcinoid Tumors of the Appendix. Ann Surg Oncol 2018;25:2391–2399. Available at: https://www.ncbi.nlm.nih.gov/pubmed/29916007.

172. AlMasri SS, Paniccia A, Hammad AY, et al. The Role of Adjuvant Chemotherapy Following Right Hemicolectomy for Non-metastatic Mucinous and Nonmucinous Appendiceal Adenocarcinoma. J Gastrointest Surg 2022;26:171–180. Available at: https://www.ncbi.nlm.nih.gov/pubmed/34291365.

173. Baron E, Sardi A, King MC, et al. Adjuvant chemotherapy for high-grade appendiceal cancer after cytoreductive surgery with hyperthermic intraperitoneal chemotherapy. Eur J Surg Oncol 2023;49:179–187. Available at: https://www.ncbi.nlm.nih.gov/pubmed/36253240.

174. Clift AK, Kornasiewicz O, Drymousis P, et al. Goblet cell carcinomas of the appendix: rare but aggressive neoplasms with challenging management. Endocr Connect 2018;7:268–277. Available at: https://www.ncbi.nlm.nih.gov/pubmed/29335251.

175. AlMasri S, Nassour I, Kowalsky SJ, et al. The Role of Adjuvant Chemotherapy in Non-Metastatic Goblet Cell Carcinoid of the Appendix: An 11-Year Experience from the National Cancer Database. Ann Surg Oncol 2021;28:3873–3881. Available at: https://www.ncbi.nlm.nih.gov/pubmed/33231767.

176. Zakka K, Williamson S, Jiang R, et al. Is adjuvant chemotherapy beneficial for stage II-III goblet cell carcinoid/goblet cell adenocarcinoma of the appendix? Surg Oncol 2021;36:120–129. Available at: https://www.ncbi.nlm.nih.gov/pubmed/33360118.

177. Blackham AU, Swett K, Eng C, et al. Perioperative systemic chemotherapy for appendiceal mucinous carcinoma peritonei treated with cytoreductive surgery and hyperthermic intraperitoneal chemotherapy. J

Version 2.2026 © 2026 National Comprehensive Cancer Network© (NCCN©), All rights reserved. NCCN Guidelines® and this illustration may not be reproduced in any form without the express written permission of NCCN.

PLEASE NOTE that use of this NCCN Content is governed by the End-User License Agreement, and you MAY NOT distribute this Content or use it with any artificial intelligence model or tool.
Printed by Máximo López Chenlo on 5/4/2026 6:12:29 PM. Copyright © 2026 National Comprehensive Cancer Network, Inc. All Rights Reserved.

Surg Oncol 2014;109:740–745. Available at: https://www.ncbi.nlm.nih.gov/pubmed/24375188.

178. Strach MC, Chakrabarty B, Nagaraju RT, et al. Defining a role for systemic chemotherapy in local and advanced appendix adenocarcinoma. ESMO Open 2023;8:101619. Available at: https://www.ncbi.nlm.nih.gov/pubmed/37625193.

179. Shen JP, Yousef AM, Zeineddine FA, et al. Efficacy of Systemic Chemotherapy in Patients With Low-grade Mucinous Appendiceal Adenocarcinoma: A Randomized Crossover Trial. JAMA Netw Open 2023;6:e2316161. Available at: https://www.ncbi.nlm.nih.gov/pubmed/37261831.

180. Lu P, Fields AC, Meyerhardt JA, et al. Systemic chemotherapy and survival in patients with metastatic low-grade appendiceal mucinous adenocarcinoma. J Surg Oncol 2019;120:446–451. Available at: https://www.ncbi.nlm.nih.gov/pubmed/31236958.

181. Tejani MA, ter Veer A, Milne D, et al. Systemic therapy for advanced appendiceal adenocarcinoma: an analysis from the NCCN Oncology Outcomes Database for colorectal cancer. J Natl Compr Canc Netw 2014;12:1123–1130. Available at: https://www.ncbi.nlm.nih.gov/pubmed/25099444.

182. Lieu CH, Lambert LA, Wolff RA, et al. Systemic chemotherapy and surgical cytoreduction for poorly differentiated and signet ring cell adenocarcinomas of the appendix. Ann Oncol 2012;23:652–658. Available at: https://www.ncbi.nlm.nih.gov/pubmed/21653683.

183. Shapiro JF, Chase JL, Wolff RA, et al. Modern systemic chemotherapy in surgically unresectable neoplasms of appendiceal origin: a single-institution experience. Cancer 2010;116:316–322. Available at: https://www.ncbi.nlm.nih.gov/pubmed/19904805.

184. Pietrantonio F, Maggi C, Fanetti G, et al. FOLFOX-4 chemotherapy for patients with unresectable or relapsed peritoneal pseudomyxoma. Oncologist 2014;19:845–850. Available at: https://www.ncbi.nlm.nih.gov/pubmed/24951608.

185. Hiraide S, Komine K, Sato Y, et al. Efficacy of modified FOLFOX6 chemotherapy for patients with unresectable pseudomyxoma peritonei. Int J Clin Oncol 2020;25:774–781. Available at: https://www.ncbi.nlm.nih.gov/pubmed/31823151.

186. Rossi RE, Luong TV, Caplin ME, et al. Goblet cell appendiceal tumors--management dilemmas and long-term outcomes. Surg Oncol 2015;24:47–53. Available at: https://www.ncbi.nlm.nih.gov/pubmed/25686643.

187. Das S, Shi C, Du L, et al. Adenocarcinoma Ex-Goblet Cell: a Retrospective Experience. J Gastrointest Cancer 2019;50:709–715. Available at: https://www.ncbi.nlm.nih.gov/pubmed/29974346.

188. Morgan RB, Dhiman A, Kim AC, et al. Doublet vs. Triplet Systemic Chemotherapy for High Grade Appendiceal Adenocarcinoma with Peritoneal Metastases. J Gastrointest Surg 2023;27:2560–2562. Available at: https://www.ncbi.nlm.nih.gov/pubmed/37308734.

189. Pietrantonio F, Berenato R, Maggi C, et al. GNAS mutations as prognostic biomarker in patients with relapsed peritoneal pseudomyxoma receiving metronomic capecitabine and bevacizumab: a clinical and translational study. J Transl Med 2016;14:125. Available at: https://www.ncbi.nlm.nih.gov/pubmed/27154293.

190. Choe JH, Overman MJ, Fournier KF, et al. Improved Survival with Anti-VEGF Therapy in the Treatment of Unresectable Appendiceal Epithelial Neoplasms. Ann Surg Oncol 2015;22:2578–2584. Available at: https://www.ncbi.nlm.nih.gov/pubmed/25582740.

191. Raghav KP, Shetty AV, Kazmi SM, et al. Impact of molecular alterations and targeted therapy in appendiceal adenocarcinomas. Oncologist 2013;18:1270–1277. Available at: https://www.ncbi.nlm.nih.gov/pubmed/24149137.

192. Elez E, Yoshino T, Shen L, et al. Encorafenib, Cetuximab, and mFOLFOX6 in BRAF-Mutated Colorectal Cancer. N Engl J Med 2025;392:2425–2437. Available at: https://www.ncbi.nlm.nih.gov/pubmed/40444708.

Version 2.2026 © 2026 National Comprehensive Cancer Network© (NCCN©), All rights reserved. NCCN Guidelines® and this illustration may not be reproduced in any form without the express written permission of NCCN.

PLEASE NOTE that use of this NCCN Content is governed by the End-User License Agreement, and you MAY NOT distribute this Content or use it with any artificial intelligence model or tool.
Printed by Máximo López Chenlo on 5/4/2026 6:12:29 PM. Copyright © 2026 National Comprehensive Cancer Network, Inc. All Rights Reserved.

193. Farquharson AL, Pranesh N, Witham G, et al. A phase II study evaluating the use of concurrent mitomycin C and capecitabine in patients with advanced unresectable pseudomyxoma peritonei. Br J Cancer 2008;99:591–596. Available at: https://www.ncbi.nlm.nih.gov/pubmed/18682713.

194. Dansby J, More A, Zeineddine M, et al. Taxane-Based Chemotherapy Is Effective in Metastatic Appendiceal Adenocarcinoma. Oncologist 2023;28:e1303–e1305. Available at: https://www.ncbi.nlm.nih.gov/pubmed/37738316.

195. Hornstein NJ, Zeineddine MA, Gunes BB, et al. Efficacy and Safety of Atezolizumab and Bevacizumab in Appendiceal Adenocarcinoma. Cancer Res Commun 2024;4:1363–1368. Available at: https://www.ncbi.nlm.nih.gov/pubmed/38709066.

196. Weitz J, Nishizaki D, Liau J, et al. Cyclin-Dependent Kinase 4/6 Inhibition as a Novel Therapy for Peritoneal Mucinous Carcinomatosis With GNAS Mutations. J Clin Oncol 2025;43:705–715. Available at: https://www.ncbi.nlm.nih.gov/pubmed/39413348.

197. Baumgartner JM, Srivastava A, Melnitchouk N, et al. A Multi-institutional Study of Peritoneal Recurrence Following Resection of Low-grade Appendiceal Mucinous Neoplasms. Ann Surg Oncol 2021;28:4685–4694. Available at: https://www.ncbi.nlm.nih.gov/pubmed/33415564.

198. Sipok A, Dort JM, Visioni A, Bijelic L. Retrospective Review of Outcomes in Non-Invasive Mucinous Appendiceal Neoplasms with and without Peritoneal Spread: A Cohort Study. Curr Oncol 2022;29:9125–9134. Available at: https://www.ncbi.nlm.nih.gov/pubmed/36547128.

199. Gupta AR, Brajcich BC, Yang AD, et al. Necessity of posttreatment surveillance for low-grade appendiceal mucinous neoplasms. J Surg Oncol 2021;124:1115–1120. Available at: https://www.ncbi.nlm.nih.gov/pubmed/34333785.

200. Nikiforchin A, Sardi A, King MC, et al. Patterns of Recurrence in Appendix Cancer After Complete Cytoreduction and Hyperthermic Intraperitoneal Chemotherapy. Ann Surg Oncol 2023;30:7848–7857. Available at: https://www.ncbi.nlm.nih.gov/pubmed/37633853.

201. Balachandran R, Thaysen HV, Christensen P, et al. Biopsychosocial Late Effects After Cytoreductive Surgery and Hyperthermic Intraperitoneal Chemotherapy for Peritoneal Metastases from Colorectal and Appendiceal Cancer: A National Prospective Cohort Study. Ann Surg Oncol 2024;31:1959–1969. Available at: https://www.ncbi.nlm.nih.gov/pubmed/38127212.

202. Ravn S, Gronfeldt JM, Thaysen HV, Iversen LH. The impact of the extent of surgery on late adverse effects following cytoreductive surgery and HIPEC. Eur J Surg Oncol 2024;50:107105. Available at: https://www.ncbi.nlm.nih.gov/pubmed/38096698.

203. Hewitt M, Greenfield S, Stovall E, eds. From Cancer Patient to Cancer Survivor: Lost in Transition. Committee on Cancer Survivorship: Improving Care and Quality of Life, Institute of Medicine and National Research Council: National Academy of Sciences; 2006. Available at: http://www.nap.edu/catalog/11468.html.

204. Jansen L, Herrmann A, Stegmaier C, et al. Health-related quality of life during the 10 years after diagnosis of colorectal cancer: a population-based study. J Clin Oncol 2011;29:3263–3269. Available at: https://www.ncbi.nlm.nih.gov/pubmed/21768465.

205. Lynch BM, Steginga SK, Hawkes AL, et al. Describing and predicting psychological distress after colorectal cancer. Cancer 2008;112:1363–1370. Available at: https://www.ncbi.nlm.nih.gov/pubmed/18318044.

206. Mols F, Beijers T, Lemmens V, et al. Chemotherapy-induced neuropathy and its association with quality of life among 2- to 11-year colorectal cancer survivors: results from the population-based PROFILES registry. J Clin Oncol 2013;31:2699–2707. Available at: https://www.ncbi.nlm.nih.gov/pubmed/23775951.

207. Thong MS, Mols F, Wang XS, et al. Quantifying fatigue in (long-term) colorectal cancer survivors: a study from the population-based patient reported outcomes following initial treatment and long term evaluation of

Version 2.2026 © 2026 National Comprehensive Cancer Network© (NCCN©), All rights reserved. NCCN Guidelines® and this illustration may not be reproduced in any form without the express written permission of NCCN.

PLEASE NOTE that use of this NCCN Content is governed by the End-User License Agreement, and you MAY NOT distribute this Content or use it with any artificial intelligence model or tool.
Printed by Máximo López Chenlo on 5/4/2026 6:12:29 PM. Copyright © 2026 National Comprehensive Cancer Network, Inc. All Rights Reserved.

survivorship registry. Eur J Cancer 2013;49:1957–1966. Available at: https://www.ncbi.nlm.nih.gov/pubmed/23453750.

208. Wright P, Downing A, Morris EJ, et al. Identifying Social Distress: A Cross-Sectional Survey of Social Outcomes 12 to 36 Months After Colorectal Cancer Diagnosis. J Clin Oncol 2015;33:3423–3430. Available at: https://www.ncbi.nlm.nih.gov/pubmed/26282636.

209. Denlinger CS, Barsevick AM. The challenges of colorectal cancer survivorship. J Natl Compr Canc Netw 2009;7:883–893; quiz 894. Available at: https://www.ncbi.nlm.nih.gov/pubmed/19755048.

Version 2.2026 © 2026 National Comprehensive Cancer Network© (NCCN©), All rights reserved. NCCN Guidelines® and this illustration may not be reproduced in any form without the express written permission of NCCN.